

Iridology FAQ Introduction

This FAQ hopes to explain Iridology simply and clearly through various theoretical and philosophical standpoints. Many questions and answers are exemplified through showing various iridological methods of study as well as practical clinical approaches to iris findings. This FAQ offers information regarding the history of Iridology including several recent discoveries of various physicians and scientists. The significance of these discoveries that involve research of iris analysis, demonstrates the continuous impact and development of world-wide specialists in bringing the science of Iridology in perspective.

Iridology can convince us that we are only as strong as our weakest tissue link. By understanding these inherent and acquired weaknesses, we are then able to properly build upon these tissues. It is important to understand that Iridologists do not name a disease after one symptom as it takes more than one organ to produce a symptom in an individual. Iridology cannot determine disease names from the iris. Instead it recognizes:

Toxins and their location

Stages of inflammation

Inherent-Genetic weakness or strength

Constitution

General health level

Biochemical deficiencies

One must be aware that Iridology is not to be used alone. It is intended for additional use in conjunction with other systems of medical sciences and Wholistic Arts.

The theory and importance of the healing crisis is shown to be an essential element of Iridology.|| Approaches and procedures in iris reading and clinical office procedures are important through the many valuable techniques that are best for both the Iridologist and patient.| The importance of clearly understanding the science of Iridology is emphasized through cautious words of knowledge in the many phases of self-development.|| A great deal of practical study is vital to the self-development of Iridology.| The objective is to obtain information, a solid history and a good background from which to work.||

Anatomy of typical and abnormal iris conditions have been well illustrated through many scientific, anatomical and theoretical foundations.|| This is exemplified through factors of inherent weakness, blood factors, racial intermarriage, eye diseases, injuries and abnormalities.|| The significance of studying reflex areas and remote symptoms is also demonstrated as an important tool in the search for underlying cause of disease.|| Studies of the density and landmark signs in the iris are represented within the construction of fibers and their relation to over-all constitution.|| This is defined through the closeness of the fibers and the fineness of structure that determines density.| It is important to realize that every landmark that is seen in the iris has its own history.|| We must consider an all-around picture and discover the cause behind the problem, and to not immediately jump to conclusions.|| Every landmark sign has its own unique story and we must read and consider the many possible inherent, chemical, reflex, nerve, spiritual and mental philosophies in an individual.||

The healing crisis is the ultimate goal for both practitioner and patient to work towards achieving better health and vitality.| It is imperative to understand the many different physical, mental, and practical aspects of a healing crisis, so we can have a better perception into what to expect when a crisis is encountered.|| In working towards attaining health, an individual must go through the eliminative, transitional, and building phases.|| The healing crisis will most often occur during the transitional stage.|| This is also the time when the practitioner does least for the patient.|| This is time to observe and learn about Herings Law of Cure in accomplishing the reversal of disease.|| It is important to know the difference between a healing crisis and a disease crisis.|| It is indicative through the appearance of acute fibers throughout the whole iris, rather than in some localized areas.|| There is usually some form of notable elimination, possible discharges, or fevers.|| However it is good to realize that this will always vary with the patient who endeavors to attain the honor of the healing crisis.||

FAQ Educational View

The basic theme of this FAQ is in relation to the educational aspect of teaching Iridology to the individual in a clear, concise, and interesting manner.|| It seems now, more than ever, that people do not know where obtain satisfactory answers concerning matters related to their health problems.|| I firmly believe that Iridology is a science and art that can be utilized in that form of education, by informing that person that there is a lifestyle to help us maintain good health.|| It is our responsibility as iridologists to educate people so they will seek the better way of life and prevention of disease.|| An informed public will make more responsible decisions with respect to health, resulting in an improved quality of life and enabling them to remain as functional and productive members of society.||

Our greatest challenge as iridologists is to educate the public.|| We must raise the awareness of the public in order to find patients interested in restoring their health.|| Our method of analysis supports this work, and all the other healing arts assist it and add to it.|| This method of analysis must be made clear, at every opportunity, that it is not a medical examination or a diagnoses of disease.|| We must inform the patient on the meaning of tissue integrity, and by no means, put any fear or worry in the subject's mind.|| We must be sensible, tactful, and wise in what we say to an individual, not only by what we say, but also how we say it.|| That is why the language of integrity is so important in conjunction with the analysis that we work with.||

└The Birth of Iridology┘

In the pictures on the ancient papyruses in the National museums of Cairo and Alexandria, temples of Luxor, which are several thousands years old, one can see many pictures in which priests investigate the eyes of pharaoh|According to the data of P|E.S. Velkhover, the priests of Ancient Egypt were able not only to make diagnosis of the existing disease, but also to make a prognosis of the future state of patient' s health, to determine the characteristic features of a person, based on the changes in the iris|On one of the paintings of the great Raphael – ‘The portrait of Baltasar Castilgnoni’ – which was finished almost 5 centuries ago, the eyes are painted very carefully. The visitors can see the eyes of older men with pronounced edemas under their eyes and the skin color, specific for patients with kidneys pathology. But what is amazing is the distinctly painted iris signs of the inborn pathology of kidneys, called ‘stacks’ . Taking into consideration the fact that the masters of Michelangelo period besides applying the brush had excellent skills also in anatomy, medicine, thus the representation of such signs is unlikely to be connected only with power of observation of the painter|

There are several documents confirming our predecessors interest and knowledge of one of the most informative ‘windows of the body’ – iris of eye| Nevertheless, the absence of the magnifying optical devices, impossibility of fixing the image and, moreover, the basis of its quantitative analysis, confined the abilities of the researchers. The results, obtained by the scientists especially during the last 15-20 years have increased considerably our knowledge about these complex exteroceptive areas of the reflected information, associated with the cerebral centers

History

According to the archeological data from more then 3 thousand years ago in India and China, there was a great deal of attention to the investigation of sense organs during disease

diagnosis. The investigation of eyes and iris changes took special role during this investigation.

In the Tutankhamen's tomb (1400–1392 B.C.) discovered by G. Carter in 1922 were valuable specimens of ancient culture and among of them the silver plates with iris pictures. The famous pharaoh priest El Ax is ascribed to be not only an ancient iridologist but popularized the diagnosis as well. Thanks to him the eye diagnostics was spread from Egypt to Babylon, Tibet, India, China and other regions.

The El Ax's papyruses and silver plates which are kept in the Vatican's library and Harvard University (A| (— Butenin) are the first known written education materials on iridology|. It should be mentioned that Egypt priests knowledge in medicine was rather high at that time.

They have described more than 300 diseases, methods of diagnostics, treatment and prophylactic. One of the factors proving high interest of ancient Egyptians to the iris structure are the statues of pharaohs and priests. Most of statues in Cairo national museum have eyes made very precisely by color mosaic. It is impossible to find two similar eyes there.

Other example can be found from the notes of the Alexander Macedonian's doctor. The warriors were selected by taking into consideration the state of their irises. The founder of one of the most enlightened dynasties of Hellenistic Egypt (305–300 B.C.) Ptholemeus, military leader of Alexander the Great, and his associates kept this knowledge and maybe transferred it to Ancient Rome after Egypt conquer.

The Ptholemeus 11, Evergot tried to find analogs between the structure of the eye and universe rotating around the immovable Earth. However this data is absent in the 'Almagest', the main proceeding of his follower Ptholemeus Klaudius (90–160 B.C

Essential attention was paid to the patient's appearance in Tibet medicine. The condition of skin, tongue, eyes, form of auricles, muscles movements etc. was estimated with great care. It was considered in particular that the eyes give information about many problems appearing in the organism. The lack of its shining and living warm meant difficult suffering of the patient.

The leading Tibet doctors carrying honorable title of 'pundit' paid supreme attention to the liver functioning and its 'screen' – eyes (the verbal translation of eyes are 'liver flower'. They made conclusions on the definite internal organs injuries by investigating the changes of iris and pupil. They called such pupil areas as windows to the body depth. The sclera and irregularities in the lower part of a pupil were regarded as blood disease symptom, the sclera and irregularities in the right part of a pupil were regarded as liver disease symptoms. The eyeball was often called as body wick showing human health state: the clean eye corresponded to the healthy condition while a murky eye – to sick. (E. Velkhover) There are interesting iris descriptions made by Aristotle, Hippocrates, Heraclitus||Velkhover), Heraclitus.

The well-known Middle Ages naturalist ‘farther of anatomy’ A. Vesalius (1514–1564) described in detail the iris of a dying man in his classical handbook about human body structure|Vesalius(1514–1564).

The Paracelsus (Fillip Teophrast – 1493–1541), founder of iatrochemistry (science about drugs), philosopher and alchemist left many descriptions of irises of sick people. He regretted that it is impossible to make more detail investigation of its structure.

The lack of optical devices didn’ t allow the study the iris structure and peculiarities of its color palette in detail. The discovery of microscope made by Antuan von Levenhuk (1632–1723) very soon had great influence on the level of iridological examinations.

In 1670 the physicist Filipp Meyens used the magnifying glass in his work. He had issued a book which contained diagnostics on eyes and eyebrows. He has divided the eye with two perpendicular lines on four sectors, each of them contained projections of several internal organs.

The first in Europe valid description of brain and lungs is supposed to be made by Dr. Mac Leiden from Holland.

The dissertation ‘De Oculo Et Signo’ (‘Eyes And Signs’) was defended in Hettingen University in 1786. In 1813 the Viennese doctor Y. Beer mention about somato-iridological links in organism in his book about eyes diseases. It is clear from his work that he never knew about ancient iridology and has made his conclusions by himself.

The ancient and Middle Ages science dealt mostly with changes of color and general eye structure. There were no basis of the method and irido-pupillary signs systematization and essentially the ability of topological investigation was not taken into consideration.

The medical doctor named Ignatz von Peczely (1826–1907) from Eger, near Budapest, Hungary has proved the basis of the method and proposed his own iris zones projection chart although rather primitive from modern point of view but relatively reliable. The scientist’ s biographers give rather interesting legend determined the mission of the future founder of modern iridology.

Ignatz von Peczely

While studying in the Viennese University and working in the surgery hospital, Peczely started to investigate the patient’ s iris changes depending on different diseases. He has found that each part of the body as well as each organ correspond to the determined iris segment. As a result the first iris chart was developed making him a founder of modern iridology. In 1880 Peczely published a book describing principles of diagnostics using iris. The main attention of his work was the location and form of iridological signs. Later he has published a manual on iris diagnostics where he wrote as epigraph that eyes are not only mirror of the soul but of the body as well. This work was met by icy silence of contemporaries.

Another important page to iridology history was added by Swedish pastor N. Liljequist|Liljequist. ‘A man can lie but his eyes never lie’ was his answer to those

who were interested in the reasons of his interest to the iridology. He has developed more detailed and reliable iridology chart independently from Peczely, determined the position of digestive tract in ciliary belt and proved that organic defect should be visible in the eyes. The color iris analysis firstly described in his fundamental book on diagnostics on eye (1897) has extended the ability to find toxic and toxic-allergic changes in the organism. The pastor was one of the first who warned that total unorganized vaccination and large doses of drugs can cause many allergic diseases in the future.

The Europeans contemporary, founder of natural therapy in Chicago, A. —. Lindlar proves in his book on iridology several principles of iridodiagnostics and natural therapy.

It should also mention about other famous names concerning the beginning of modern iridology: E. Schnabel are concerned with the beginning of the use of the objective methods in iridology in 20th century. For the first time H. Hense has included iris photo pictures into his manual and R. Schnabel began to use microscope instead of magnifying glass.

Established by M. Madaus in 1920 journal 'Iriscorrespondens' has increased the activity of iris diagnostic practitioners at that time.

Many papers on iridology were published at the end of 19th and the beginning of 20th centuries. Most of them were the proceedings of single investigators. Sometimes they were not reliable and had no respects to medicine. The problems of clinical approval concerned with low technical level of equipment at that time, the lack of mutual efforts of laboratories, hospitals and universities often led to false conclusions even conscientious scientists. The contradictory results and projection interpretations, sometimes personal antagonism among scientists led to the decrease of trust to the method as well as to its followers.

The evolution of the method in new history was mainly in national schools what led at the beginning to some disagreements but further allowed to create matched system of projection zones and classifying signs by combination of different charts.

B. Jensen (born in 1908) is one of the outstanding persons in modern iridology. Natural medicine doctor, Nutritionist, chiropractor, philosopher and author of widely spread in the world manual on iridology. His book, The Science and practice of Iridology details a method which allows to determine the patient's condition without interception to the organs functioning. One of the main advantages of iridodiagnostics is that signs of constitutional peculiarities, genetic defects and structural damages of organism appear on the iris significantly earlier than real dysfunction or pathology appears, i.e.

Dr. 博士 Jensen investigated more than 350,000 patients during fifty years. The iris charts developed by B. Jensen are one of the most spread in the world. The approach to the iris structure, its density, amortization, pigment and other properties is original and confirmed by clinical practice. His theory on the rules of iridogenetic inheritance the signs forming and conservation is the basis of modern understanding of iridological prognosis.

It should be also mention about his great contribution to the unification of iridologists all over the world. In 1951 he has established international association of iridologists and natural medicine doctors (FIA) and for a long term he was the president of the association.

(1) The iris reveals, through changes in pigment and structure, abnormal conditions of tissue in the human body; (2) The anterior of the iris reflexly corresponds in the systematic organization of its topography to the major tissue structures the body. For example, each organ, gland and tissue is represented in a specific location in the left or right iris, or both. *** The documentation in support of these two central hypotheses is established on the work of hundreds of primary health care professionals that have used Iridology successfully as a diagnostic aid with thousands of patients in the past 100 years. The accuracy and reliability of iris signs as reflex indications of tissue pathology in the body have been confirmed in many thousands of instances by: laboratory tests, X-rays, and other commonly accepted diagnostic approaches.

(3) Organs and tissues on the left half of the body are reflexly represented in the left iris, while those of the right half of

the body are represented in the right iris.。 Organs and tissues lying along the centerline of the body, the sagittal plane, appear in both irides, as do bilateral organs.

The anterior iris, including the anterior epithelium, the stroma, the muscle layer, the pupillary margin, the autonomic nerve wreath (collarette), and the scleral-iris margin undergo specific changes corresponding to pathological changes in specific organs and tissues in the body.||

*** Again, this hypothesis is based upon findings and empirical observations of hundreds of Iridologists.||***

Iridologists have distinguished that the iris changes due to pathological deterioration of body tissue.|| This shows as a whiteness (acute) in the iris fibers, then an increasing darkness (sub-acute -> chronic -> degenerative) and the depth of iris lesions.|| In the past, Iridologists have also stated that they have witnessed changes due to reversal pathology (emergence of healing lines.)|| in the same iris lesions after successful treatment.|| In many cases these findings are confirmed with other commonly accepted diagnostic procedures.|| It must be emphasized that the pathological condition must be adequately severe to be classified by the standards of western medicine as the classification standards of Iridology are different.|| The various laboratory tests that are being used to determine the presence or absence of disease are not totally efficient in the assessment of subclinical conditions.|| Acute and sub-acute stages of tissue inflammation can commonly be detected long before other diagnostic methods are capable of finding any health problems with the patient.|| In a similar manner, when a patient is declared "well" by the standards of Western medicine, Iridology frequently shows a subacute condition persisting in the individual||

Authors Note: The iris is comprised of a genetically based cryptic leaf that is genotypic and does not change (No valid Proof exists) therefor you will only see changes in pigments, transversals and in the borders of certain lacunae.|| There are examples of Iris changes in certain Iridology books such as Jensen II and Deck books although the Jensen study is questionable due to photographic techniques used.|| The Deck book shows a very good example of pigment change over a period of 10 years.|| In most cases, one will mainly find the iris pigment(s) to become more clear after treatment or cleansing of the body.|| Most recently, ?macro 3D imaging is now being used to show changes in the iris although these techniques need more scientific peer review.|| Iris photography is very difficult because the least amount of light or change in environment can change pupil size thus give the effect of change in the iris.||

German medical researcher, Walter Lang, has demonstrated that the autonomic nerve fibers from virtually every gland, organ and tissue of the body extend to the thalamus and hypothalamus which monitor and respond to changes of condition in all anatomical structures.|| These changes of state, Lang suggests, are relayed from the thalamus and hypothalamus through the ophthalmic branch of the trigeminal ganglion to the motorneurons of the iris muscle structure.|| Changes in the impulses conducted by these motorneurons may be responsible for the changes in the muscle structure of the iris, leading to the gradual separation of iris fibers in the stroma and consequent appearance of the lesions and other markings familiar to iridologist.|| Lang also points out that the organization of the human nervous system is genotypic, and further postulates that innervation to the iris reliably represents is also genotypic, which accounts to the fact that the iris reliably represents the same organs, glands, and other anatomical subdivisions of the body in precisely the same locations in the irides of all individuals.||

Hypothesis #5||

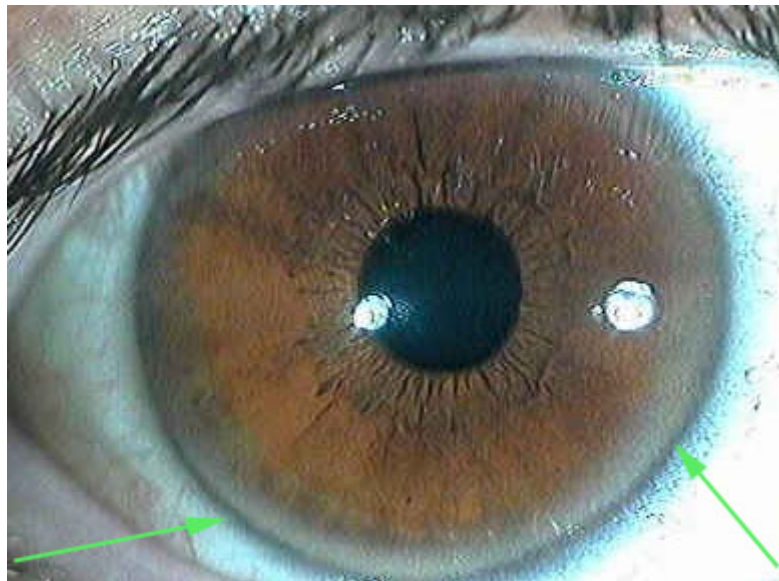
Inherent weaknesses, inherent strengths and the degree of nervous system sensitivity are shown in the iris, respectively, by the crypts and separations in the trabeculae; by closely knit trabeculae; and by parallel, curved cramp rings concentric with outer perimeter of the iris, all located in the ciliary zone outside the autonomic nerve wreath.||

*** Scientific research has demonstrated that the posterior pigment epithelium and dilator muscle of the irides are embryologically derived from neurectoderm, the tissue from which the central nervous system (brain and spinal chord) are also derived.||*** Iridologist find that it is this similarity that reflects in the iris the genetic inheritance of the individual.|| It is assumed that the specific configuration and development of the dilator muscle somehow determine the radial arrangement and spacing of the vascular arcades (trabeculae) in the stroma above it.|| The fact that crypts and separated trabeculae represent inherent weaknesses in no way conflicts with the fact that the same structures allow aqueous humor to circulate through the irides.?)||

Conditions to Consider||

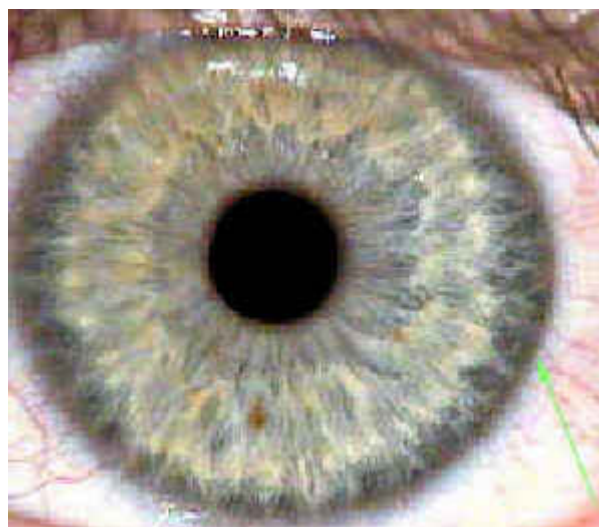
Listed are just a few iris signs that are commonly looked for in iris analysis in North America.|| Many other Iridodiagnostic approaches can be found throughout the world.||

SODIUM / CHOLESTEROL RING



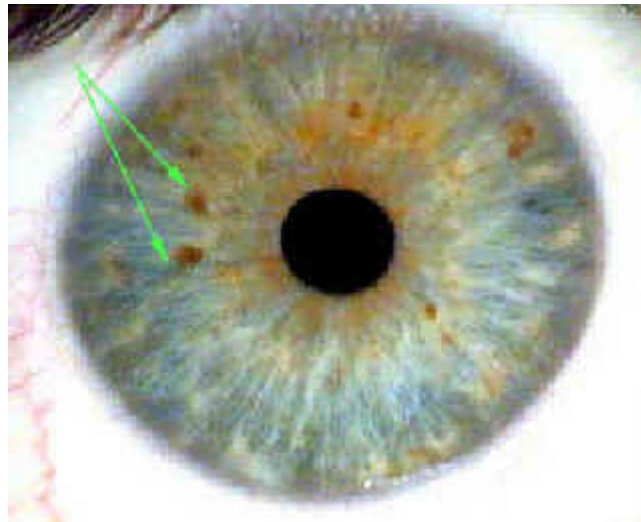
This sign is a result from a chemical imbalance in the body, pertaining to non organic sodium excess, calcium out of solution, as well as high cholesterol and high triglycerides in the blood.|| Cholesterol Ring is also a non-specific liver marking.|| It may transpire when hepatopathies (liver disease) diabetes mellitus or hypo-activity of the thyroid are present.|| When there is a problem with the inorganic sodium and excessive fats in the body, there may be hardening of the arteries, calcium spurs and deposits, joint problems and so on.|| This does not necessarily mean that the blood levels of cholesterol are high but indicate there is an imbalance of fat metabolism.|| The cholesterol ring is a white, opaque ring that appears around the outer edge of the iris either partially or wholly. ?||

VENOUS CONGESTION



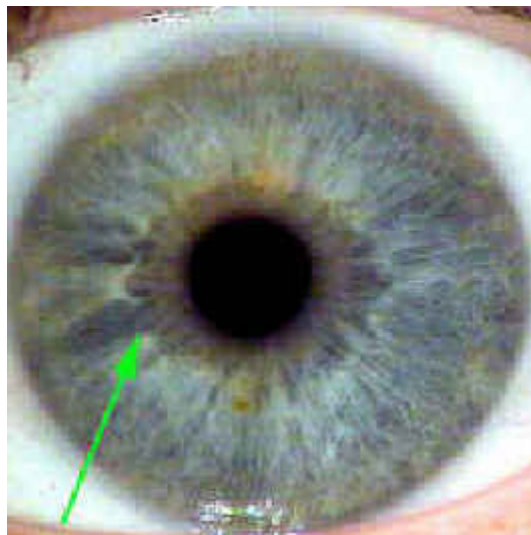
This condition is represented by a hazy bluish ring surrounding the outer perimeter of the iris.|| This indicates a lack of oxygen in the body.|| Lack of exercise and iron anemia are common causes.||

DRUG/ CHEMICAL DEPOSITS



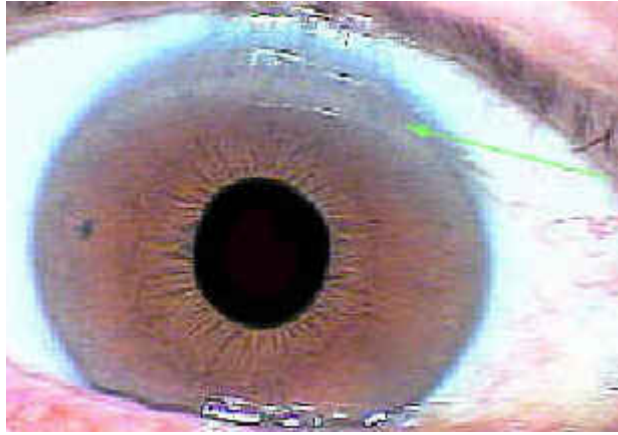
There are the small reddish-brown discoloration's in the iris that may be inherited or acquired.|| These discoloration's are referred to as inorganic chemical substances, that are deposited in weaker tissues of the body.|| The Iridologist cannot determine which particular drug is deposited, because of the presence of so many possible chemicals in our food, air and environment.||Iridologist The areas concerned, have less vitality to throw off drug accumulations.|| These may be relatively harmless but may also irritate the tissues, creating more chronic problems.|| These discoloration's will lighten up in time with continued cleansing procedures.||

POOR NERVE SUPPLY ??||



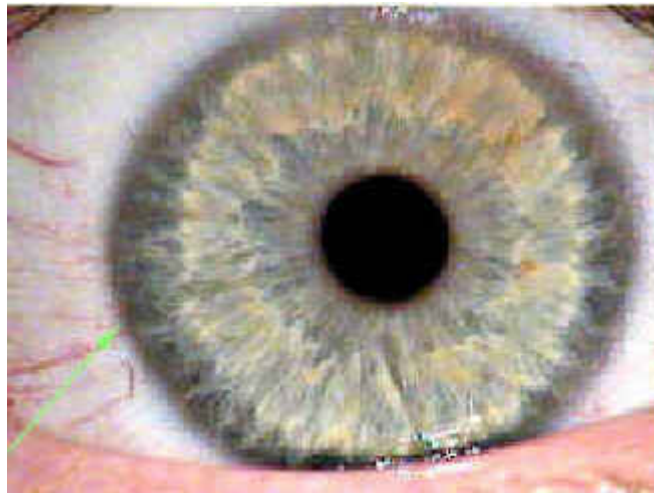
As indicated, specific areas that have weakened nerve supply as seen in the autonomic nerve wreath.|| A poorly defined wreath represents a weakened autonomic nervous system and intestinal insufficiency.||

CEREBRAL ANEMIA||



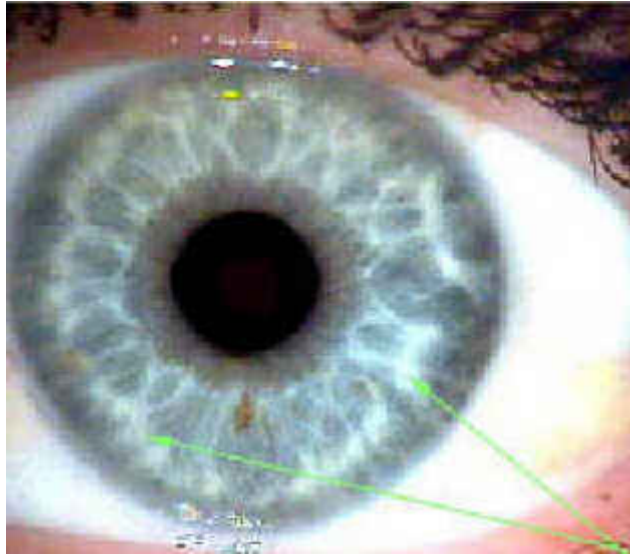
This shows as a lack of circulation in the cerebral/brain area.|| When there is a lack of circulation, there is also a lack of oxygen, as well as specific chemical elements.|| Gravity does not help matters at all but is recommended, if possible, that slant board exercises would benefit this area greatly. ?|| Leg "pump" exercises also benefit cerebral anemia.||

UNDERACTIVE SKIN||UNDERACTIVE



The skin is a very important part of our elimination system, throwing off an average of two pounds of waste per day!|| It seems that if the kidneys are not functioning properly, it may cause an excess of wastes being eliminated through the skin.|| This is also true in the reverse.|| White round flecks known as tophi may be found opposite a dark skin area indicating elimination processes are restricted by poor action of the skin and to compensate there will be catarrhal formation.|| To keep the skin more active, it is best to find clothing that is not tight fitting.|| Skin brushing with a vegetable bristle will loosen away dead skin improving elimination.||

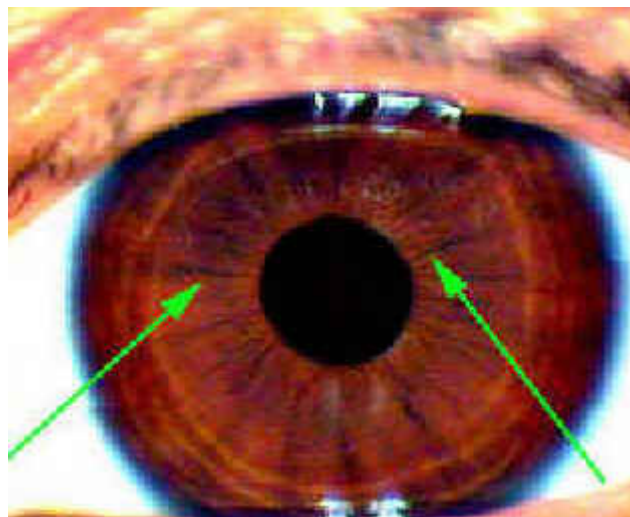
LYMPH CONGESTION



The lymph system has many responsibilities in the body.|| Some of these are; eliminating pathogenic microorganisms, returning important proteins and fluid to the blood, absorbing fats in slow safe amounts and takes a most important role in our body's immune system.||— The thymus gland, tonsils, appendix, peyer's patches and spleen are all part of the lymphatic systems.||

When there is congestion, there is a lack of proper circulation of this fluid.|| Lymph fluid, unlike blood, travels only in one direction and does not depend on the heart for movement.|| Exercise, especially walking is the only way to move the lymph fluid along properly.|| It is noteworthy that the lymph system is a sodium organ and that there is much more lymph fluid than blood in the body!||

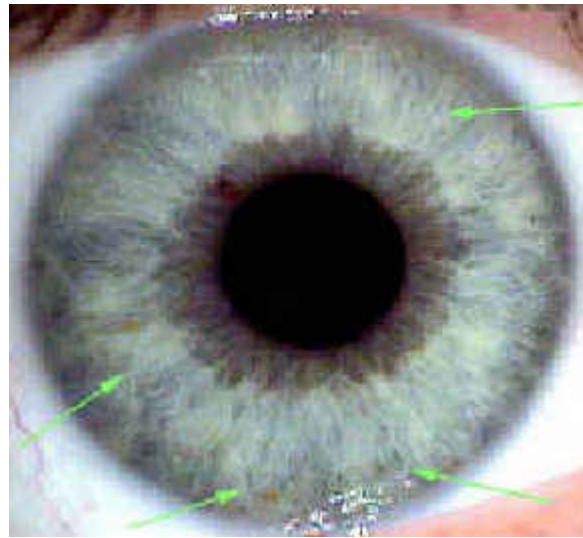
RADII SOLARIS



This sign resembles the spokes on a bicycle wheel.They appear as dark brown/black grooves in the iris and are seen radially from the frill outwards with the base wider than the tip. They represent inherent weakness in the bowel area and are indicative of a toxic, slow moving bowel. This is most commonly found in the biliary iris as a constitutional sign. When these are found to be pronounced in the iris, special care may be needed to take care of the bowel. Radii Solaris are also usually associated with sinus problems, toxic headache and other toxic symptoms. Radii solaris indicate nerve weakness and are a sign of insufficiency to the organ, gland and tissue field areas they disperse to in the iris. If seen in

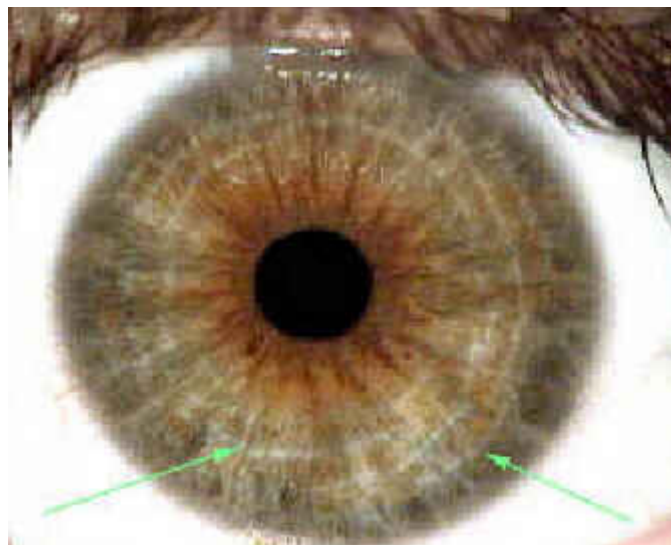
the adrenal gland the subject is likely to tire easily. If seen to be piercing the heart or kidney zones, a circulatory problem could result.

BODY ACIDITY



This may be caused from a variety of conditions such as diet, state of mind or under functioning of one or more elimination systems. Often all of these associations being involved to some extent. One cannot think sweet thoughts with a sour stomach, as well as one cannot digest foods properly if the mind is not thinking correctly! Stressful, negative thinking can turn a healthy diet into nothing more than a poor diet. In order to overcome excess acidity, it is best to look at all aspects that create acidity in the body. Foods high in organic sodium and potassium, help in the neutralization and elimination of acids in the body.

NERVE/ STRESS RINGS (Contraction Furrows or Adaptive Rings)



Adaptive rings and arcs (also called nerve/stress rings) are depressions in the iris stroma and also be referred to as neurovascular cramp rings, cramp rings, contraction rings or nerve rings. These may be inherited or acquired but either way shows the individual has some degree of nerve tension or anxiety. They can also indicate mineral deficiencies, especially calcium.

In today's lifestyle, it is not uncommon to find that the majority of people have some degree of tension, reflected upon

their job, relationships, financial, etc. Nerve rings can vary from light to heavy, depending upon the degree of nervous tension in the individual. When we see a nerve ring pass through the thyroid gland (the emotional gland), this represents extreme emotions that can be portrayed in the individual. Stress rings are commonly seen in the anxiety tetanic constitutions.

Iridology and Constitution

We perceive a constitutional iris by its defined shade of color to the degree of its primary shade that is characteristic for that specific constitutional type. Constitution is the whole of an individual's inherited and acquired characteristics. It represents the reactive capacity of an individual in establishing the capability for adaptation. Constitutions are genotypic and expose specific kinds of pathological processes that may occur in an individual. There is no implication that a specific disease is inherited but only the individual factors that compose a predisposition are inherited.

Constitutional types are perpetually mixed and may be diverse. Subtypes are inborn and exclusively modified through life. Such modifications include certain environmental influences and external factors during the course of life acting on the person including their reactions to such conditions (career, stress, trauma, domestic, nutrition, etc).

The strength of an individual's constitution is proportional to the integrity of the iris fibrous trabeculae network. Fibrous integrity is a measure of anatomic strength in an individual to counteract negative external influences. The greater density found in the iris shows a higher resistance the body has towards such external influences. A diathesis exposes a genetic pathological condition that is conditioned by the constitution representing a sensitivity and susceptibility to illness. A physiological disease marking represents a diathesis and is expressed by the phenomena of deposition.

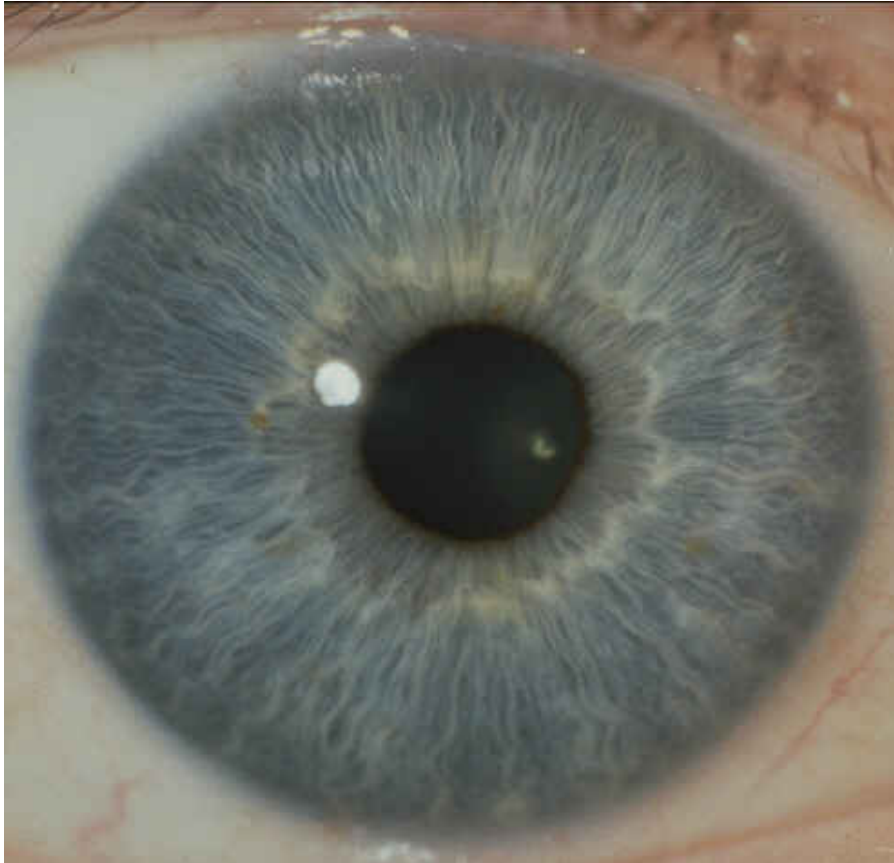
The three main categories (Lymphatic, Haematogenic and Biliary/Mixed) are furthermore divided into "sub-types" in order to include commonly observed variations in behavior. Please observe that certain pathological processes are not entirely limited to only one type of constitution and that any one type of constitution only demonstrates statistical and theoretical disadvantages toward particular disorders. Constitution gives us a picture of the overall strength in the body. People with a strong constitution tend not to have as many illnesses, and when they do, they seem to recover quite quickly. These are the type of people that usually grow up abusing their health because they can get away with it without no ill consequences. They also tend to be less receptive to someone with a weaker constitution thus showing little consideration to their needs. It is good to note that someone with a very good constitution can only burn the candle for so long.

Those with a weaker constitution have a greater amount of inherent weaknesses in their body. They need to take extra care of their body more than someone with an inherited strong constitution to stay well. They are more sensitive to foods, environment, stress and tend to take longer to recover from illnesses that occur more frequently than someone with a strong constitution.

Iris Constitution according to Joseph Deck|

(several sub-classifications of constitutions are not listed)

Lymphatic

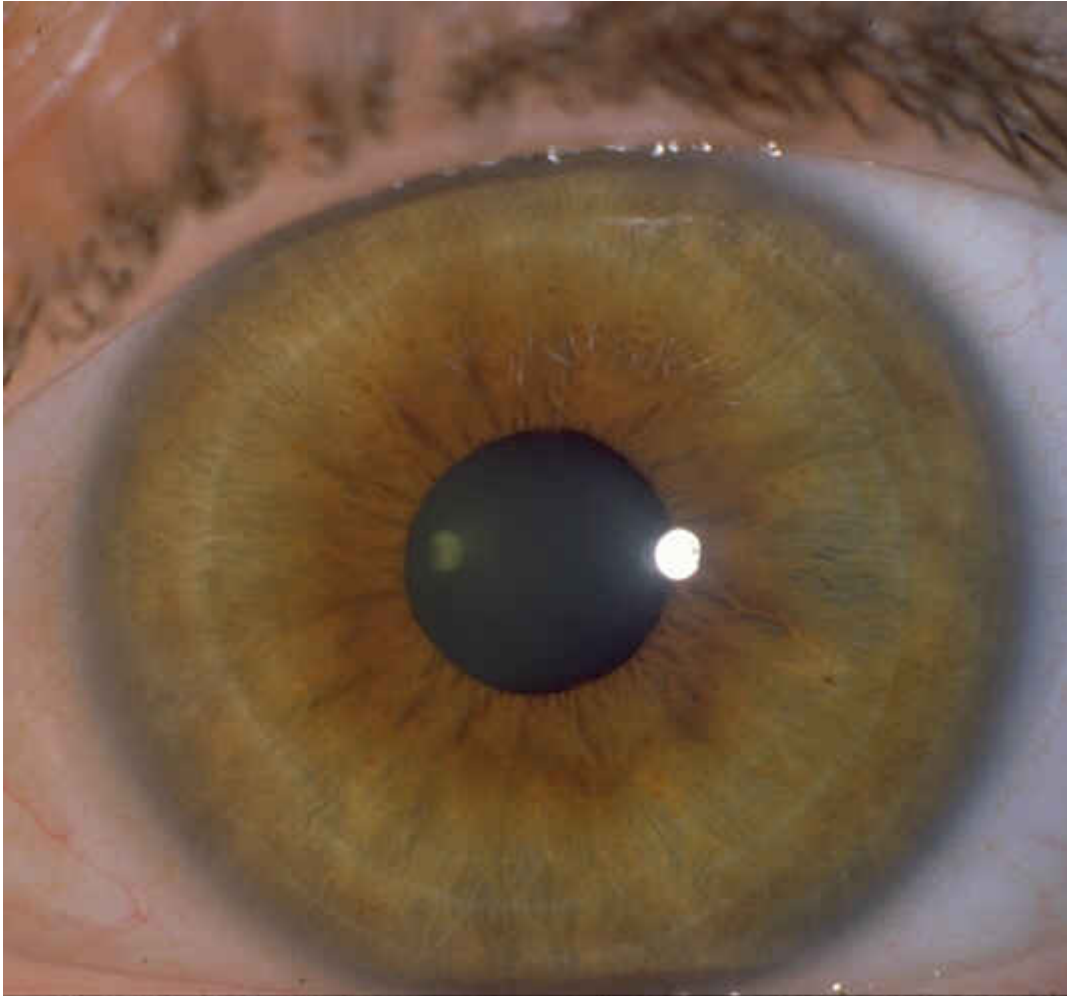


Lymphatic is the blue eye due to lack of melanin pigment.

This type of constitution have tendency toward excess mucous production with discharges focusing in the respiratory, alimentary, and urogenital tracts.

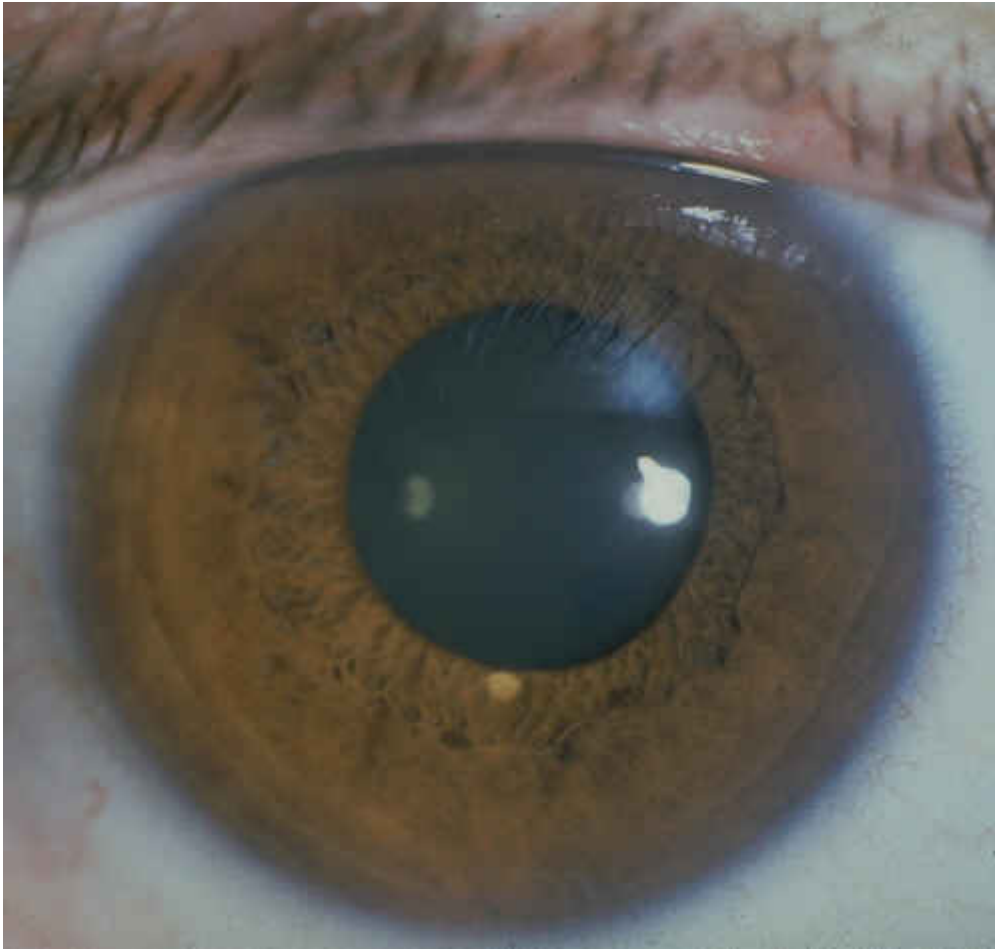
Often found in these types are overactive immune system and allergies, over acidity, and lymphatic congestion with a tendency towards arthritic, rheumatic, ezcematic, and psoriatic conditions.

Billiary/Mixed Brown



Seen as a light brown pigment with overlaying visible white/yellowish fibers. Tendency often associated with liver, gallbladder, and associated digestive disturbances often aggravated by dietary disorders.

Hematogenic/True Brown

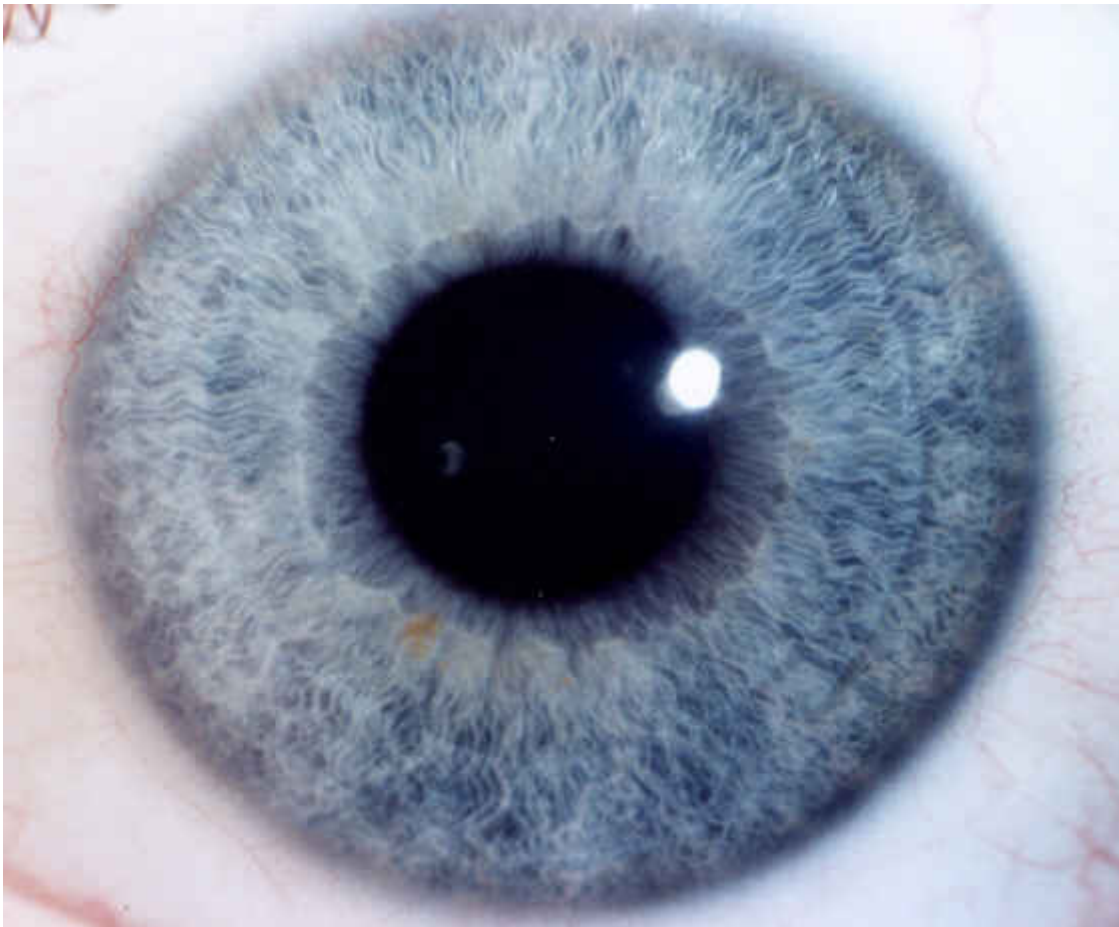


Seen as a brown pigment "carpet" obscuring iris and fibers. Tendency often associated with blood composition, liver, gastrointestinal, and glandular disturbances.

More on Constitutional Types & Subtypes

More Information on 34 Constitutional Types and Sub-Types can be obtained from obtaining the book "Constitutional Classification Via the Eye" by Bryan K. This particular book contains several more constitutional sub-types, iris images and constitutional therapy.

Neurogenic Sensitive or Neurolymphatic Constitution



Description

Lymphatic constitutional sub-type distinguished by delicately arranged iris stroma with bright white blood and lymph region. Thin, tight, uniform and stretched trabeculae are distinct from the characteristic wavy pattern of the pure lymphatic type. Fiber density is exceptional showing good resistance.

It is possible to experience rarefaction in the lung-pleura-rib and the uro-genital areas. Iris sectors corresponding to the pleura, genitals and bladder also frequently show combed hair-like formed bundles. The “combed hair” appearance (Maubach) affirms a constitutional weakness in those sectors of the body. One must then examine for reflexive signs such as vascularizations and transversals in these areas. Not characteristic but may occur in this type: small or wide pupils, neurasthenic rings, solar rays, dark skin margin, dark kidney field, circular contraction furrows, light blood and lymph region, transitional forms shading into the lymphatic constitution.

Inclination and predisposition

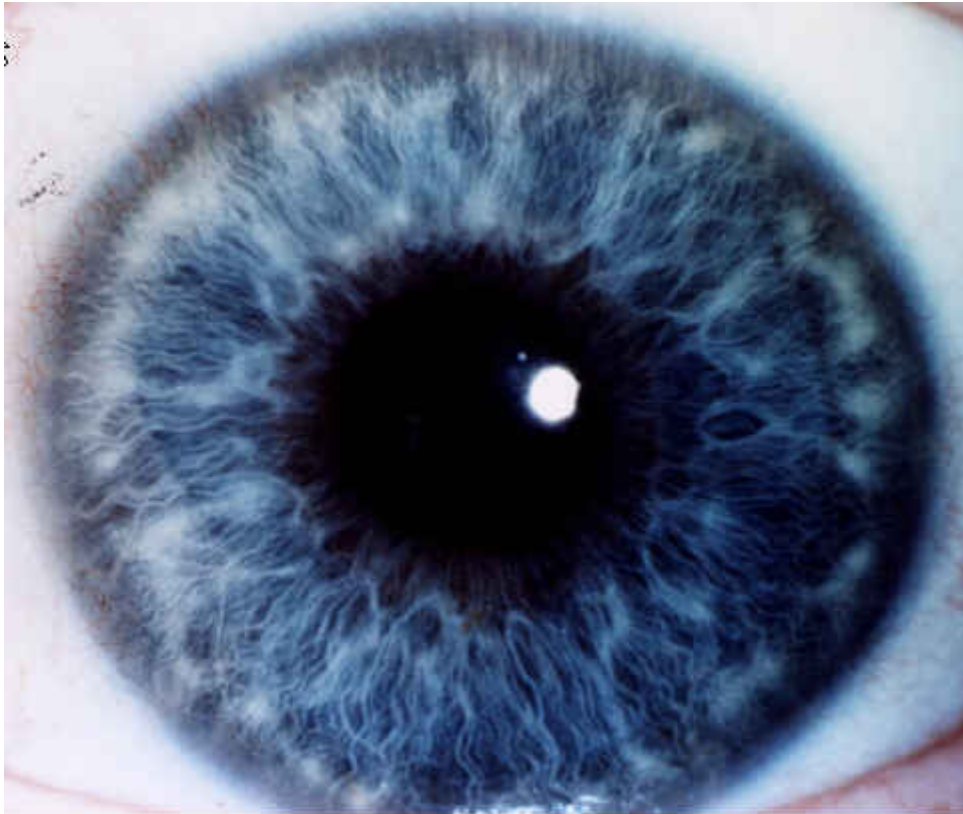
Sensitivity of central and autonomic nervous systems with inclination toward nervous disposition and other anatomic organ disorders due to autonomic dysfunction.

Afflictions of this constitutional type are produced by a highly sensitive nervous system which under stress, can fall target to critical problems such as neuralgias, nervous breakdown, exhaustion, neuritis, trembling, nerve pains, multiple sclerosis, poliomyelitis, Parkinson’s disease and chorea. The formation of blood is weak resulting in mineral deficiencies. Physical dispositions include diabetes, liver-kidney disorders, pneumonia, diarrhea, vicarious bleeding, and various inflammations. Subject to headaches, migraine due to vascular spasm, vascular weakness, vascular crisis with particular risk for cerebral vessels (strokes), nervous hypersensitivity, exhaustion, irritability and general weakness of the central nervous system. Inclination towards skin eruptions (herpes, shingles) correlated with the nervous system. Frequency and severity of symptoms diversify according to the degree of resilience.

The pupil border should be examined and any pupillary deformations noted in relation to cerebral circulatory risk, spinal

subluxations, nerve root obstruction, and possible psychological disadvantage. If pupil deformation is observed, psychosis may occur. Manic – depressive mood swings are potential in this type. Immoderate bodily, mental or emotional stress can deteriorate the patient into an over-burdened nervous system. This can influence multiple functional disorders of vital organs such as the stomach, intestine, heart, circulation, thyroid gland, endocrine organs, etc. ? Usually thin reactive types that are easily distracted and forgetful. These patients are remarkably sensitive to outside feedback, which can produce an internal uneasiness. ?

Hydrogenoid - Hydrogenic Constitution



Description

Lymphatic sub-type constitution characterized by condensed, rounded, well-defined, less converging, white to off-white tophi, with beginnings of pigmentation. These bundles of connective tissue stroma are called tophi. Tophi are also mentioned as the lymphatic rosary but does not fundamentally mean that the lymph system is stagnant. It primarily points to a propensity to this condition.

Tophi are connective tissue bundles detected in the outer ciliary zone. They range in appearances from clear to poorly defined and white to yellow-brown in color. They frequently emerge in the mucous membrane zones of the lung, breast, neck, groin, diaphragm, sinus and nasal areas. Discolored tophi (yellow/ brown toxic inclusions) with unclear borders suggest a strong inclination to chronic lymphatic congestion.

Lacunae and defect signs in the respiratory tract may indicate various inherent disease backgrounds such as allergies and rheumatoid arthritis in the family history. A predominance of ancestral tuberculosis may be present if tophi are distinct in the lung-pleura-rib reaction field. Observe for tophi in the outer areas of the iris, nasally and temporally.

The hydrogenoid subtype is most commonly seen in the lymphatic eyes although it can be occasionally present in mixed biliary type. In this occurrence, digestive errors are the major cause of lymphatic congestion.

Inclination and Predisposition

A medium to strong rheumatic inclination with acute rheumatic illnesses invading the joints is indicated. A disposition to catarrh with an exudative diathesis exists.

This classification exhibits either latent or active antigen-antibody reaction (allergy). The appearance of endogenous

substances (cellular waste, metabolized exudates) will keep the immune system attentive though not inevitably active. Exogenous substances (foods, pollens, dust, etc.) can irritate this type with exudative responses including eczema, bronchial asthma, diarrhea, arthritis, bronchitis and rhinitis.

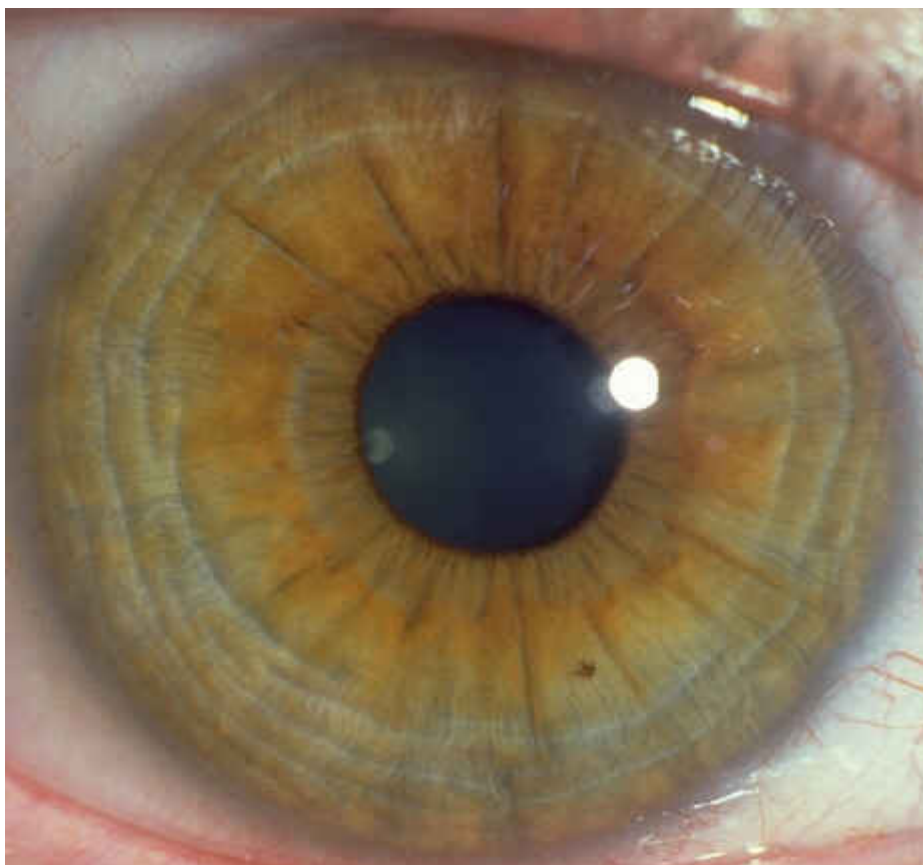
Predispositions include faulty elimination, lymph stagnation, metabolic waste accumulation in the kidneys, lymph and intestines although dormant until other target sites become congested from toxins and irritate surrounding tissue. There is a tendency to retain fluids. In detecting sluggish target sites and drainage points, observe for typical texture and shading iris signs. ?

Tendency towards rheumatic distress most notably in colder weather. More frequently colds, asthma, arthritis, bronchitis, and reactions to dampness may occur in this type. This type never seems to be totally free of complaints although symptom occurrence increases dramatically when tophi are distinct and discolored.

Disease pathology may arise from inadequate lymphatic drainage, poor resistance, inadequate kidney detoxification, toxically influenced and functionally diminished mucous membranes, weak digestion, difficult protein assimilation. Dysbiosis may also be present.

Particular physical dispositions involve swollen lymph glands, rhinitis, runny or stuffed nose, food allergies, allergic asthma, coughing up phlegm, wheezing, eczema, skin rashes, weather related rheumatism, cold hands and feet, easily chilled, soft tumors.

Vegetative Spastic Pathological Constitution



"Larvate Tetanic Sub-Type"

Description

This type may also be identified in the lymphatic diathesis or haemotogenic/mixed iris dyscratic diathesis.

These formations are primarily found in the upper and lower lateral quadrants. These radial fold formations have been named congestion furrows, aberrant radial furrows and parchment rolls. Additionally there are also circular fold formations specifically found nasally which appear as light rings set into pigmentation. These circular formations are often described as "cramp rings" but also known as circular contraction furrows (Schnabel, stress rings (Jensen) and nerve rings (Jensen). ? The Vegetative-Spastic Constitution (Schimmel) is considered a pathological constitution and has

a tendency to display the similar phenomena as the (Deck) Anxiety Tetanic Diathesis.

Predominantly dyscratic iris with radial fold formations spreading outwards from the frill extending as far as the iris edge with others partly only to the center of the ciliary area. Numerous bright or dark Contraction furrows spread throughout the iris indicate this diathesis. Lighter rings show a more acute nature than with dark rings displaying more chronic manifestations. Partial or total arcus senilis may also be apparent. ?

Both phenomena occur mostly together in that radial folds will often break the circular folds. The circular folds can appear in different variations as listed:

Staggered

Centrally parallel to pupil and edge of iris

Short ring segments

Large ring segments

Respective rings parallel to one another

Respective rings, sometimes overlapping

These contraction furrows are theorized that a buckling of the trabeculae in the ciliary zone produces them. This reaction is created by perpetuated contraction of the dilator muscle characterizing abnormal tension in the sympathetic nervous system (hypertonia).

Josef Deck had classified this sub-type under the Haematogenic mixed category as he has found this phenomena in 90% brown eyes compared to 10% blue eyes (Lymphatic). Current research has found this percentage inaccurate as lifestyle changes have changed dramatically in the past 50 years.

Breaks found in contraction furrows can serve as a sign for the chiropractor as they are focal points for neuromuscular activity. Broken areas found in an iris section may correspond to specific organs or muscle zone being influenced by irritation and/or spinal subluxation.

Inclination and Predisposition

Three or more circular furrows may appear broken revealing spasmodic tendencies and potential spinal subluxations due to elevated neuromuscular tension.

May display nervous tension with psychosomatic tendencies including increased neuromuscular activity.

Contraction furrows have a tendency to increase the intensity of other latent signs and dispositions.

Inclinations to diseases such as peripheral circulatory disturbances, dysthyroidism, parathyroidism, vertigo, arrhythmia's, angina pectoris, gallbladder, renal or ureteral colic, pelvic congestion, tachycardia, headaches, apnoea, laryngeal spasm, jaw clenching, palpitations, epilepsy and heart stress. Vegetative-spastic disorders with spastic diathesis, peripheral circulatory disorders, and dysmenorrhoea with pelvic congestion and backache. The tendency towards headaches, migraine and gastro-intestinal spasms are predominant in this type. Spastic conditions disturbing circulatory disorders and blood sugar metabolism errors.||

Gastrointestinal disorders such as nervous stomach, intestinal spasms, colitis and ulcers.

Neuromuscular stress such as tense muscles, Frequent stiffness in arms and legs, pains in hands and lower legs, bloatedness, general muscle pain, nervous pain, migraine, persistent headaches, itching, feeling of coldness may be presented in this type. ? Tendencies towards sensory disturbances such as hypersensitivity to noise and light and occasionally sense of smell with difficulty in breathing.

This classification thrives off stress and may portray Psychological manifestations such as compulsive weeping, agoraphobia, depression, mood swings, hysteria, impatiently, abdominal complaints, excessive emotions, excitability and other anxiety type behaviors. ?

Tendencies towards the use of artificial stimulants to compensate in declining energy reserve. Often highly ambitious, motivated and highly diversified.

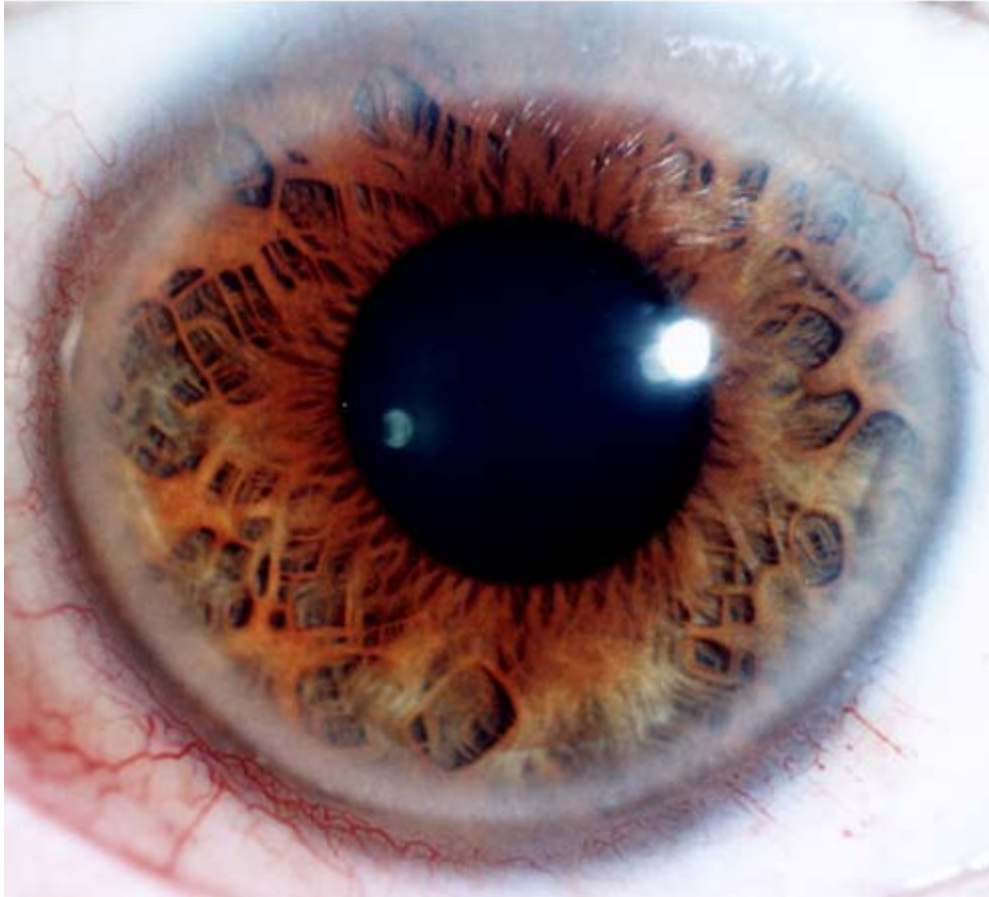
Deck emphasized the relation of inherent hypocalcemia and hypoparathyroid in the anxiety subtype.

Neuromuscular irritability increases in proportion to the degree of hypocalcemia. ??

People with this constitution generally have a greater need for calcium, magnesium and vitamin B complex, a deficiency of which may make the mentioned inclinations inferior. The general vegetative-spastic diathesis has a lessened mental-emotional and physical capacity for stress as a consequence. These patients are quickly exhausted. Adequate rest

and relaxation is essential. Eliminate all artificial stimulants including foods high in sugar. Exercise is vital to release a buildup of muscular tension. Stress reduction such as meditation, quietness, and stillness.

Weak Connective Tissue type - Mesenchymal Pathological Constitution



Description

Lymphatic type characteristics showing a blue tone and displays profuse abundantly woven increased stroma with large open weakness signs. Occurs predominantly in the blue although frequently in all primary constitutions. Constitutional mesenchymal weakness with pathogenic result is attributable to genetically inferior connective tissue.

Inclination and Predisposition

This iris phenomena can be seen in irides of any color, however it appears to be more regularly found in blue irides and categorized as a sub-group of the lymphatic constitution described by Josef Deck.

The iris consists of connective tissue and includes all networks of communication in the body which also comprises of blood vessels, Lymphatics, vascular and neural networks. Connective tissue is not only a support system but also acts as a transport route between the capillaries and the organ cells. If the connective tissue is insufficient then interaction within the body is inadequate. Every human cell is directly or indirectly contingent on the function of the connective tissue.

Inborn weakness of the connective tissue, weakness of the ligaments and tendons with tendency to ptosis, uterine prolapse, weakness of the arterial walls and inclination towards varicose veins, hemorrhoids and phlebitis. Weakness of the entire connective tissue support system, even in the parenchymatous organs. Genetic weakness in this constitution causes difficulty in all organs and organ systems. Immune system response can be defective in this type.

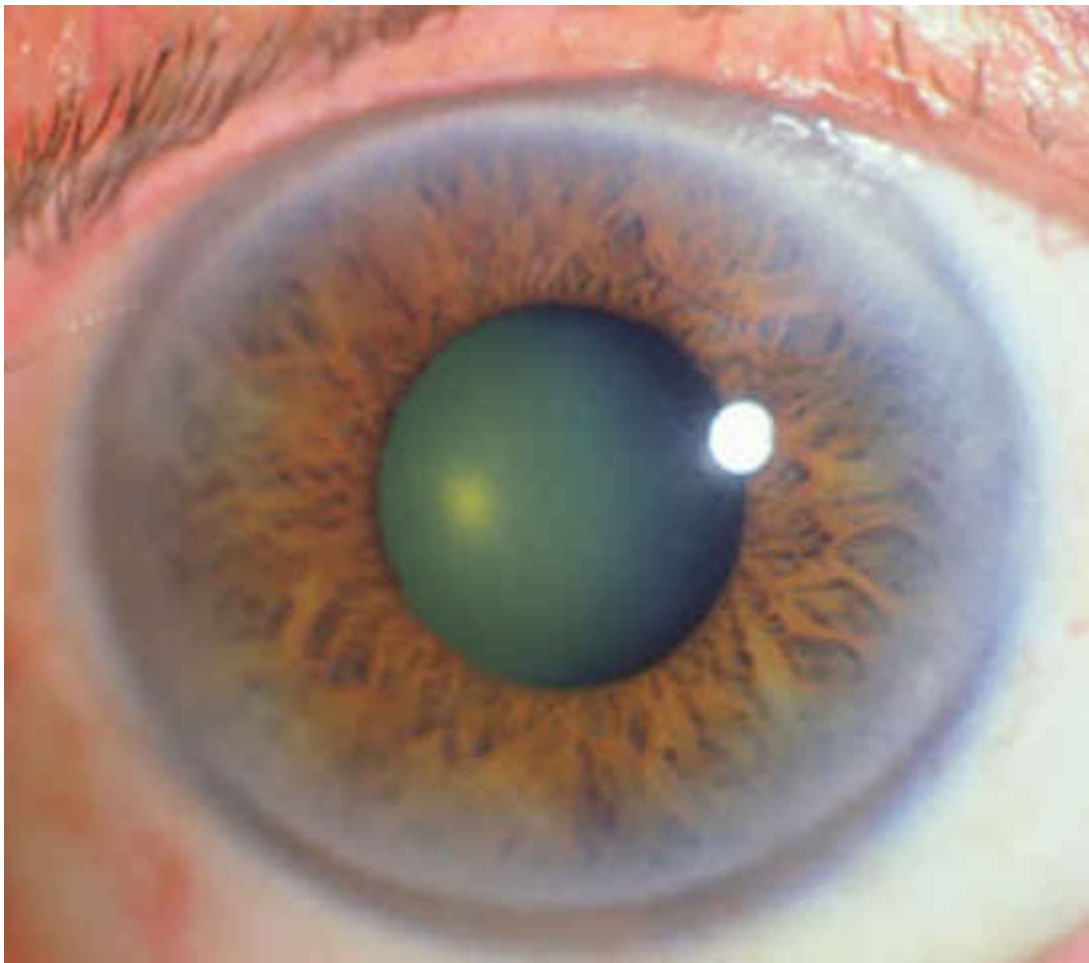
Connective tissue weakness can result in a gradual accumulation of waste via the kidneys and connective tissues. Connective tissue weaknesses will influence the falling of organs such as the alimentary tract and lower abdominal organs (prolapse). (prolapse) Hernias and varicose veins are frequently present because there is an insufficiency of support for metabolic functions of the organs. Inclination to structural problems includes the knees and ankles with a

tendency towards buckling. Spinal symptoms frequently exist. Minerals do not hold efficiently in the body, especially calcium and magnesium.

Specific physical characteristics include a disposition towards connective and elastic tissue weakness. These can include varicosities, prolapsus of organs, fracture, ptosis (particularly abdominal), uro-genital, spinal anomalies (subluxations), hemorrhoids, scoliosis, and postural difficulties. Only during infancy through to finished growth development can one successfully carry out constitutional treatment in this type.

Genetic weakness in other organs with acquired weaknesses is especially serious in these individuals because the providing of oxygen and nutrients with the removal of waste products becomes inadequate.

Lipaemic Pathological Diathesis



Description

This particular constitution does not exist as a distinctly defined constitution, since it can also be a diathesis. It is a cornea sign and not an iris sign. The cornea has an opaque circular band or an arc over the iris which can also be seen partially, although more notably in the external or cranial zones of the iris.

Theorized to be a combination of fatty degeneration of the corneal cells with calcium deposits indicating a genetically determined disease of metabolism. Due to the aqueous humor, the iris is a very sensitive tissue that indicates a regulated metabolism. An emergence of organic disease due to endogenous cholesterosis and coronary sclerosis become more apparent with age. The correlation with sodium imbalance has been discounted by many clinical studies.

Inclination and Predisposition

Fifty percent of individuals with a corneal arcus have high cholesterol. A ratio of 2 to 1 disadvantage towards atherosclerosis and related diseases is predominant in persons who show this phenomena.

Chiefly found in people between ages of 30 plus and indicates a serious potential for stroke. It is a typical aging sign when seen in later life. It has also been established as a genetic sign. Due to a genetic endogenous disposition, one may even see the arcus phenomena in individuals that are vegetarians.

In coronary sclerosis we may see fine radial irritation marks in the heart zone of the iris. A black rim becomes visible encircling the whole circumference of the iris next to the sclera when respiration becomes impaired.?

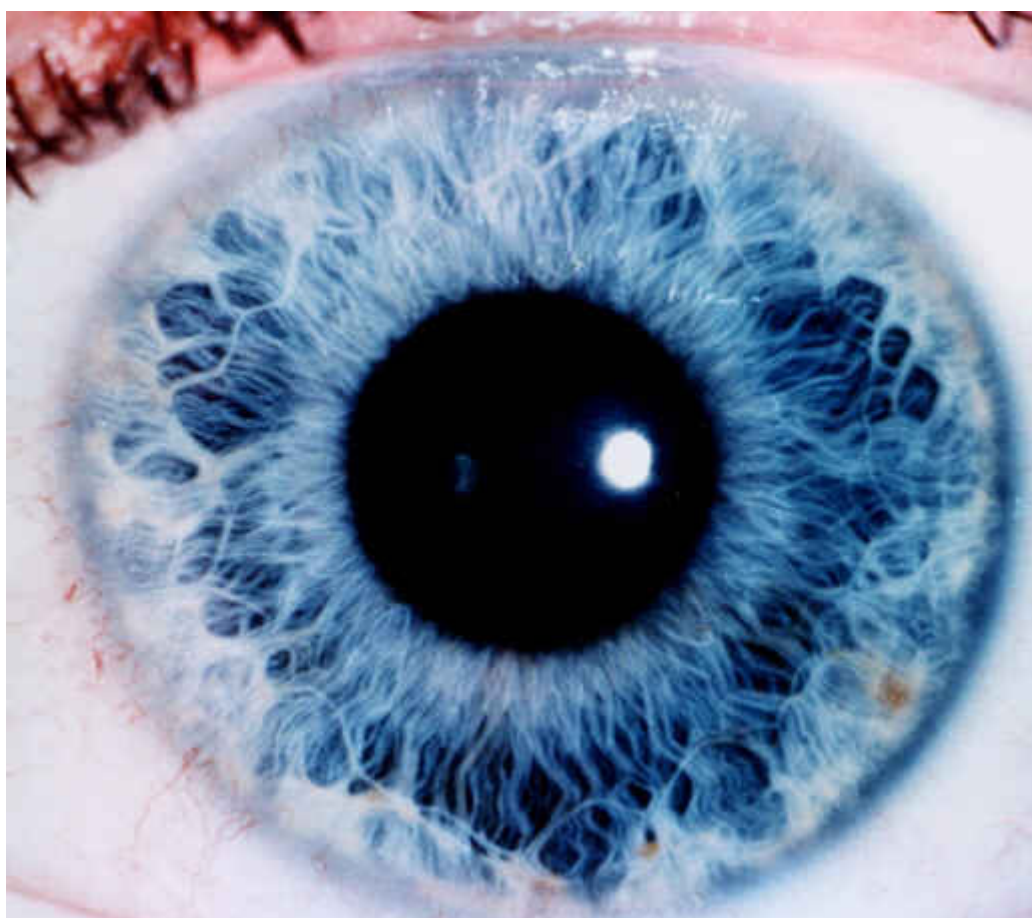
The arcus indicates that there is a tendency towards raised blood lipids producing premature fatty deterioration of cells in organs and systems such as heart, liver, skin, vessels, premature arteriosclerosis, etc.||

Specific physical dispositions include: weak connective tissue, arteriosclerosis, high lipid count, angina pectoris, heart weakness, influenzal infections, stroke, peripheral circulatory problems, vascular necrosis, venous thrombosis and ulceration's, poor digestion and absorption of fats, liver congestion and sluggishness, metabolic disorders of the liver, bile ducts, and pancreas. ? ?When an inferior Arcus emerges in the lower position of the iris then the femoral, iliac and distal (hip, thigh and leg) arteries are being obstructed by plaque material. By the time the opacity appears the patient may be suffering complaints of the lower extremity related inadequate circulation.

When a superior Arcus emerges in the upper portion of the iris then the vessels that supply the cranium are indicated. If the arcus emerges on the medial or temporal side, the vascular supply to the main body of organs especially heart and lungs are considered.

Corneal Arcus indicates a chemical imbalance, liver dysfunction and disturbed fat or glucose metabolism. A yellow lipid deposit in the sclera shows further evidence of a disturbed fat metabolism and indicates high cholesterol or excess blood fats.

Cardio Abdominal Syndrome



Description

Cardio Abdominal Syndrome is a sub-division of the Weak Connective Type. This type is also referred to as Roemheld Syndrome after Dr.?

This syndrome is distinguished by a large lacuna in the heart region with or without defect markings. The left colon is

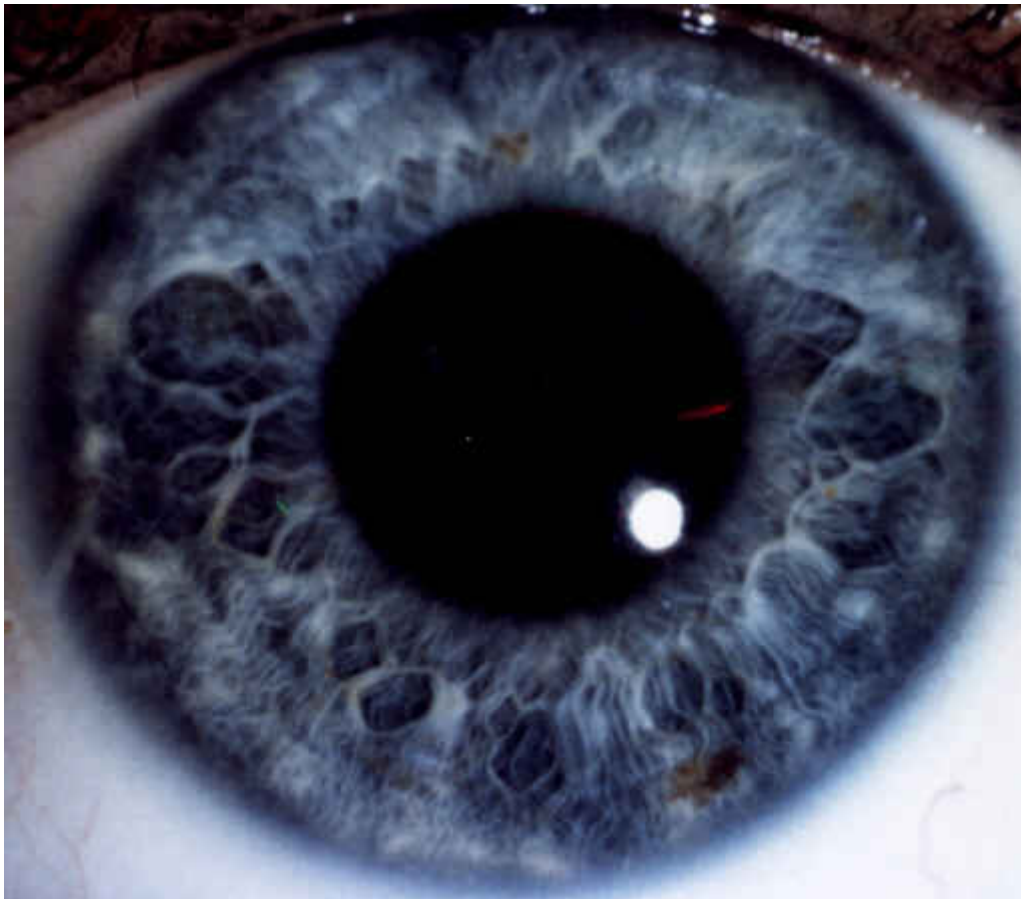
remarkably illustrated by lacunae as an abdominal marking for organ weakness. Defect markings can be found within or without the colon area. Substantial distention of the collarette will exist in the splenic flexure or descending colon section. This is an inherent weakness with formation and congestion of gas.

This syndrome demonstrates a cardiac risk based upon mechanical pressure from the superior displacement of the large intestines. A local distention of the collarette reveals colonic deficiency, weak tonus tendencies toward prolapsus or displacement. The colon can also be the central point in serious disturbances of bacterial flora imbalance and toxic accumulations. The heart lacuna is a genotypic sign with a prognosis of functional weakness under accumulated stress and circulatory disturbance.

Inclination and Predisposition

Dysentry and its various forms, abdominal distention, weak connective tissue, flatulence, heartburn, constricting in chest, anxiety or agitation felt in chest, sensation of pulse in throat, cardiac dyspnea and faintness. ?

Pancreatic Syndrome

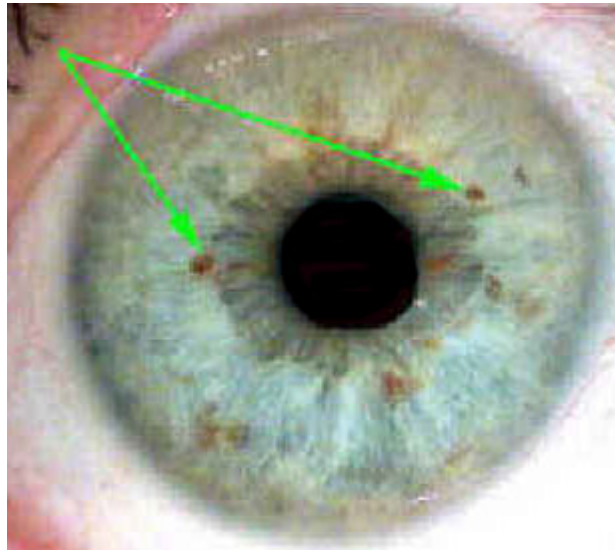


Description

The Pancreatic Syndrome is a sub-division of the weak connective tissue type. Dispersed and loose radial fibers indicate weak connective tissue. Iris exhibits honeycombs and lacunae in pancreatic sector and in the pulmonary bronchial zone. This syndrome indicates hereditary weakness of both pancreas and bronchi. ?

Tonsil hyperplasia can be found in this syndrome. Bronchial weakness in infancy is primarily heredity and frequently linked with pancreas fibrosis. This phenomenon can be detected in young children and exhibit diseases such as measles, whooping cough and recurrent infections that can lead to bronchi-pneumonia, pleurisy, tuberculosis and other lung/bronchi alterations.

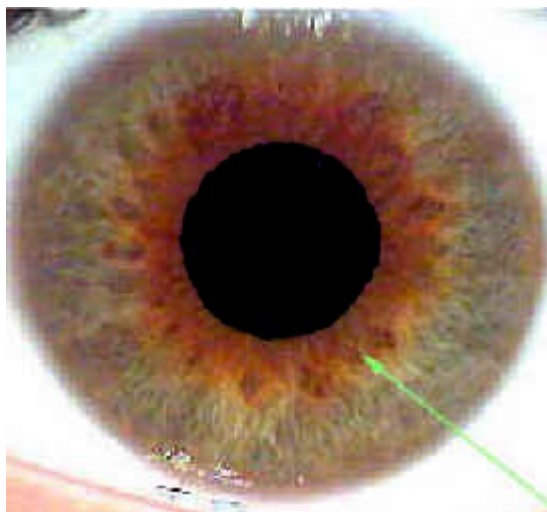Iris Color & Iris Pigmentation



The human iris can be seen in a number of various colors, although there are only two basic iris colors, blue and brown. It seems more than ever, through so much inter-marriage of races in the world that we are likely to see a genetic mix of colors. There are many instances where drug and toxic settlements in the body, can make the Iris color appear different from its basic predominant color. It is difficult to determine what type of inorganic drug has settled in a specific weak tissue because so many drugs and chemicals are being used in our world today compared to 100 years ago.

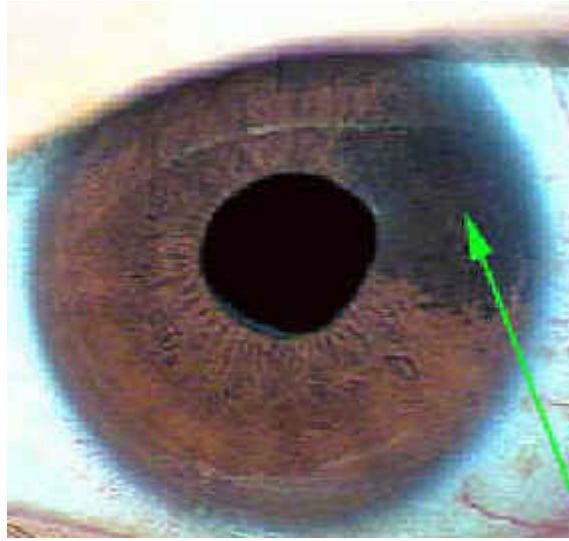
The signs of certain drugs as quinine, iron, and coal tar products have been noticed approximately two months after administration, but other metallic poisons, such as mercury, lead or plumbum, usually take up to a year to be demonstrated in the iris. These drug signs that show in the iris indicate the amounts of the drug the system has failed to eliminate, not the quantities of the drug being used.

Central Heterochromia



A highly pigmented area that appears around the pupil and spreads outwards towards the edge of the iris. This type of pigment may not be relevant to iris analysis unless it spills over the collarette thus indicating candida overgrowth syndrome. Conditions of gastric sub-acidity and hypochlorhydria may also be indicated. A common sign found in the biliary constitution. ??

Sectoral Heterochromia



A term given to an iris when part of the iris is genetically pigmented, usually in one section. This is quite rare and has no significant meaning as of yet. ?

Brown Pigment ?is usually seen in diabetes. This pigment is as a result of either the liver not sufficiently

detoxifying or inadequate production of trypsinogen (which breaks down protein) by the pancreas.

Brown/Red Pigment in the iris indicates a pancreas problem.

Fuscin Pigments are yellow brown pigments over the liver/gall bladder area and the pancreatic head. This type of pigment usually indicates dysfunction of the gall bladder. Fuscins are substances which develop during the break down of hemoglobin and its derivatives in the liver.

Lattice Pigment a net structure with a very large mesh and irregular fringe edge. It is black/brown in colour and occurs rarely. It is very large and often covers a part of the iris from the collarette to the ciliary edge. The lattice pigment indicates a disposition to diabetes, chronic liver disease and ?formation of tumors.

Orange/Yellow Pigment ?inside the collarette indicates a problem with protein metabolism and shows putrefaction of protein. When seen outside the collarette kidney malfunction is indicated. ??

Pancreas Pigments are dark brown spots of pigment which seem to 'float' on top of the iris structure. Their position is not significant. ??

Pigment Spots are dark brown spots appearing at random throughout the iris. These indicate liver and pancreas malfunction. High or low blood sugar conditions should be suspected. ? Pink/Yellow Pigment in the iris outside the collarette indicates a kidney problem.

Red/Yellow Pigment in the iris indicates a pancreas problem. ?? Rufin Pigments are red pigments and when seen in the liver zone with vascularized liver transversal may indicate carcinoma of the liver. ??

Yellow/Pink Pigment in the iris outside the collarette indicates a kidney problem. ?

Yellow Pigment associated with the kidneys and digestion and usually develop in the lymphatic iris type or by a high intake of meat products. Yellow pigment may develop in the kidney zone or the intestinal zone. ???

Yellow/Orange Pigment in the iris inside the collarette indicates a problem with protein metabolism.

Black Hair Pigment clearly seen as a pigment spot with black hair on the surface of the iris. This sign appears mostly in the middle or peripheral part of the ciliary zone. The black hair pigment may indicate cancer of glandular organs.

Black Pigment when seen in isolation is said to indicate cancer of the corresponding zone. ??

Candida Overgrowth Syndrome Pigment seen in the iris as a dull brown pigment spreading from the pupil and spilling

over the collarette producing a central heterochromia. This indicates abnormal overgrowth of candida albicans. The following is a list of a few drugs and inorganic chemicals that have been associated with certain types of localized and specific iris pigments.

Mercury or Hydrargyrum - Quicksilver

In a blue eye, Mercury shows up as a whitish or silvery gray circular line of a metallic lustre in the circulatory area of the brain region. The brown eye will display a more blue or greenish tint.

Lead or Plumbum

This drug may be seen in the iris as a lead blue, or bluish gray circular discoloration in the stomach - intestines region. Although this drug has an affinity for the intestines, other organ areas may also have settlements in severe cases.

Iodine

No other drug shows up more clearly than iodine although signs will differ according to internal or external absorption. Internal absorption will show up as a bright red, reddish brown, or orange colored spots that sometimes have a white border showing irritation and inflammation, or process of elimination. External absorption shows up as an orange or pinkish hue, and appears in the form of streaks or clouds. This drug sign can show up in any area of the iris, although more frequently in the liver, kidneys, gastro-intestinal, lungs, pancreas, and brain areas. Iodine pigmentation is always a brighter red and more diffuse than psora

Psora or Itch Spots

Psora may be seen as dark or muddy brown spots that can range in various sizes, and can be found anywhere in the iris. These spots will appear after the suppression of itchy eruptions or parasites. It has also been noted that these spots may be indicative tubercular or malignant tendencies.

Quinine

Depending on certain chemical combinations associated, Quinine shows as a yellowish, cloudy discoloration or sometimes greenish cloudy hue. Quinine has an affinity to settle in the brain areas, eyes, ears, and digestive systems.

Bromides

Bromides show in the outer-most iris area closest to the sclera as a whitish or yellowish white crescent with the affinity to settle in the brain and nervous system areas. Bromides are used heavily in the pharmaceutical Industries.

ArsenicEarly stages of arsenic pigmentation will show as a grayish-white veil like specks over the gastro-intestinal or respiratory areas. Later stages shows up as grayish white flakes and may appear singly or irregular groups in the circulatory area.

Phosphorus

Phosphorus can show up as whitish, grayish, and faded yellow specks and clouds in the gastro-intestinal, brain, limbs, diaphragm, and heart areas. May appear a lighter amber color in brown eyes..

Aluminum

May show up as blue-gray spots in the circulatory area.

Sodium

Sodium will show up as a slight metallic lustre in the circulatory or lymphatic areas. This ring may fully surround the iris or may be found in parts depending on the quantities of inorganic salt not eliminated in certain circulatory areas.

Sulphur

Sulphur shows up in the gastro-intestinal area producing a yellow or dark brown, sulphur like color. When the sulphur sign is seen in the iris, irregular conditions in the autonomic nerve wreath may be seen indicating a sluggish condition in the intestinal tract.

Creosote

Creosote produces a fine grayish or ashen gray veil over the whole iris. Long term cases will show up as sparkling white

spots in the stomach or intestinal areas.

Strychnine||Strychnine

Strychnine shows in the iris as a white wheel-like circle in proportion around the pupil in the stomach area. close inspection may find lines or spokes radiating from the pupil.

Ergot

Ergot shows as a series of bright red, sometimes rust-brown spots in the gastro-intestinal tract and may sometimes be found as bright red spots throughout various organs in the iris. It is also seen at times as a red or rust-brown circle in the stomach area.

Glycerine

Glycerine shows as large white spots or clouds in the skin, kidneys, and lung areas.

Salicylic Acid|

Salicylic Acid shows as a whitish gray cloud or veil spreading unevenly over the outer margin of the iris, being more pronounced in the upper part. It is frequently associated with the sodium ring. This drug also has an affinity to the gastro-intestinal tract.

Ferrum or Iron

Ferrum & iron will show up as a rusty-brown discoloration of the entire gastro-intestinal tract.

Bismuth

Bismuth ingestion will show as dark-gray irregular circles in the digestive tract.

Vaccine Virus

Vaccine Virus shows as a distinctly superficial black or muddy brown spot. This spot is always surrounded by white indicating that the virus is causing irritation, creating an inflammatory area around it. Vaccine virus has the tendency to darken the entire iris and may also cause white lines to appear in the liver, spleen, and bladder areas for reason of elimination.

Opium

Opium is seen in the iris as pure white straight lines radiating from the pupil or the autonomic nerve wreath outward. This is most noticed in the upper part of the iris.

Morphine

Morphine is similar to opium although appears in the iris as finer white lines which are very superficial.

Cocaine

Cocaine is similar to that of morphine as it appears in the iris.

Nicotine

Nicotine is similar in appearance to that of the vaccine virus in portraying the dark, smokey effect. In heavy smokers, it is common to find a number of nerve rings and some abnormalities in the autonomic nerve wreath (collarete).

Iris Pigmentation and Constitution

It seems that people with a brown eye have a family history that goes back to the more southern climates, while blue eyes have a history of a family background in the northern climates.

It has been noted that brown eyed people seem more subject to glandular and blood related disorders while blue eyes seem to be subject to lymphatic, catarrhal and acidic disorders.

Other localized and specific pigmentations indicate reduced functional organ capabilities or increased susceptibility to stress.

Some examples are::

Straw Yellow - Kidney

Orange - Pancreas & Liver

Fluorescent Orange - Gallbladder, Pancreas and Liver

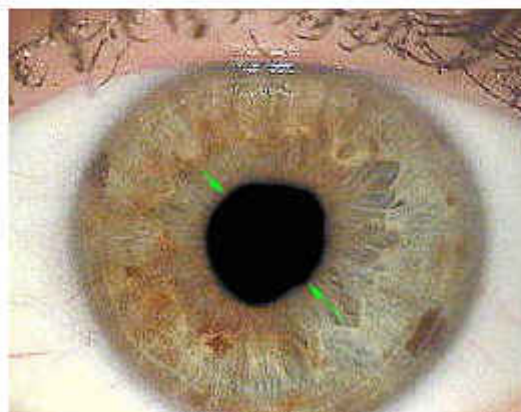

Brown (light, medium, dark, reddish) - Liver

Black/Tar - Pre-cancerous & liver

Pupil Deformations

Deformations of the pupil are primarily changes that are affecting the inner margin of the iris by paralysis or irritation of the nerves controlling the muscles of the iris. Total deformation, in that the natural form diverges toward an oval shape, is believed to suggest a disturbance with the central nerve association. Partial deformation, or sectoral flattening, is an indicator for evaluating the condition of the central nervous system in relation to organs whose areas are concentrated in the section of the iris corresponding to the flattened segment. The ordinary functioning of the nerves to all areas of the body can be dispersed by misalignments of the vertebrae. Examination of pupil tonus can identify problem areas of the spine. ?

Left Oblique Ellipse




Observe for left-sided paralysis, sexual disturbances, lack of strength and energy in the legs.

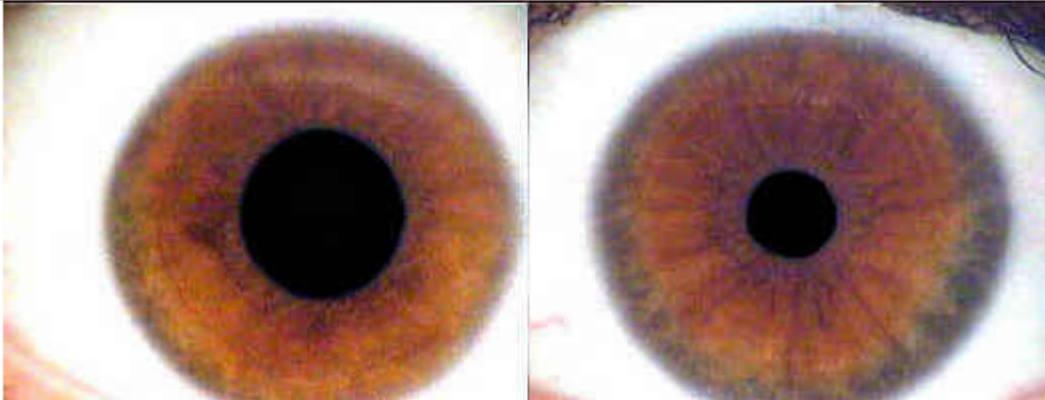
Unequal Pupil Diameters

Unequal Pupil Diameters

Anisocordia

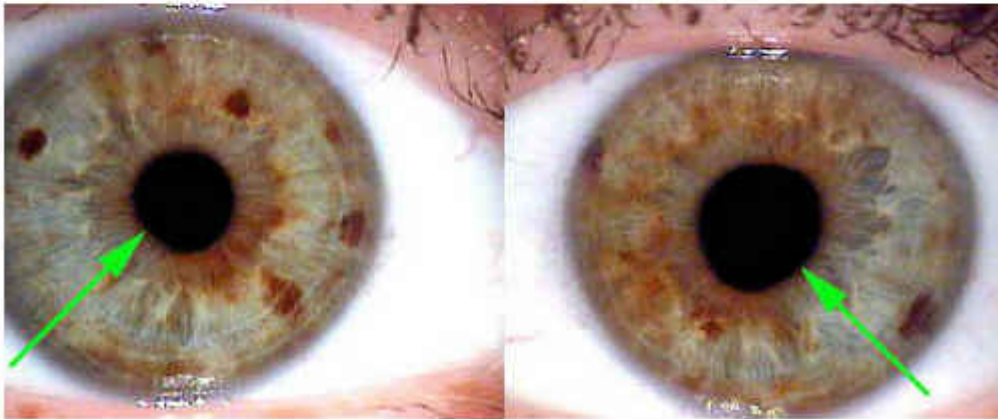
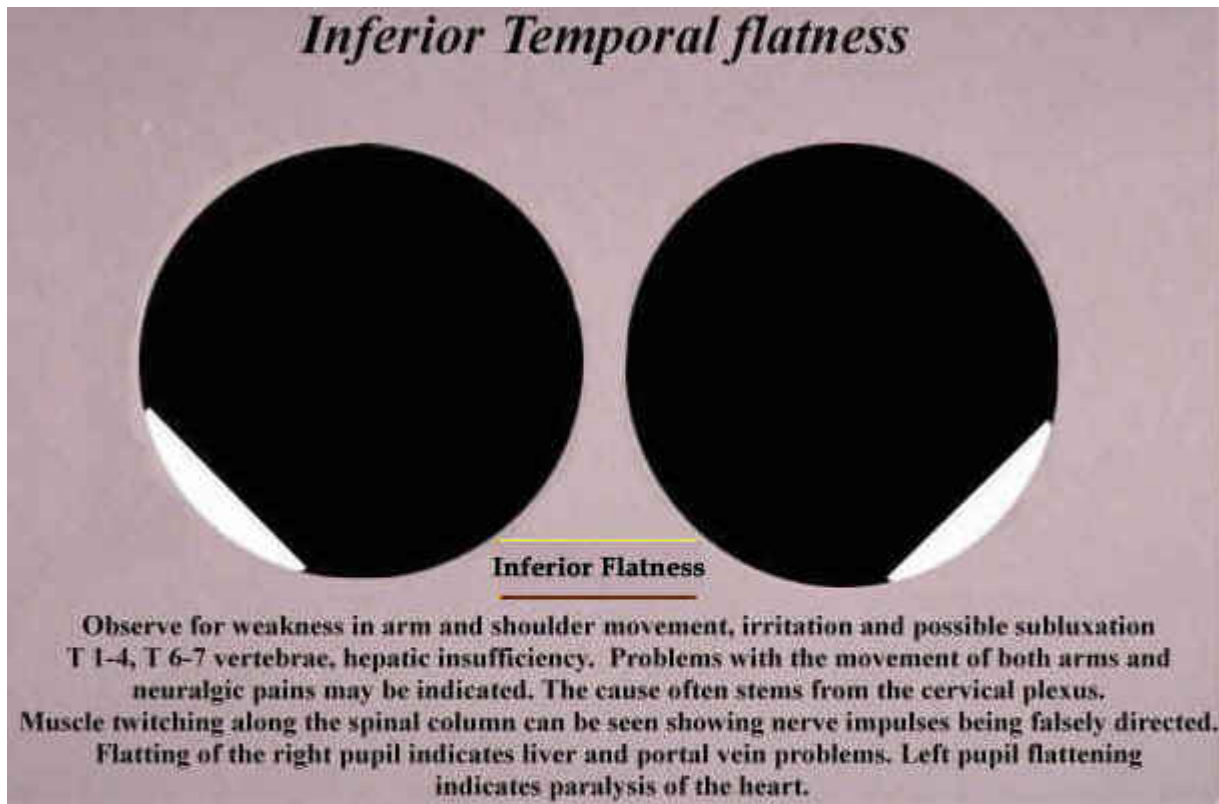


Potential history of diphtheria or meningitis, possible background of hereditary syphilitic damage.



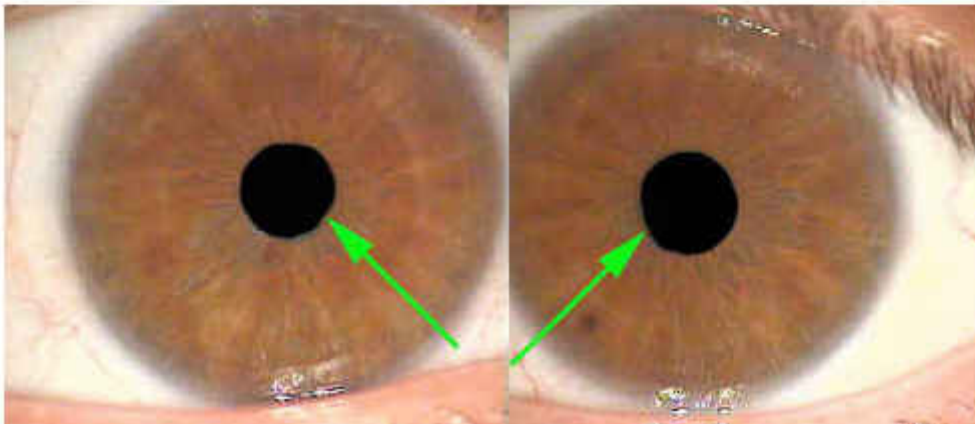
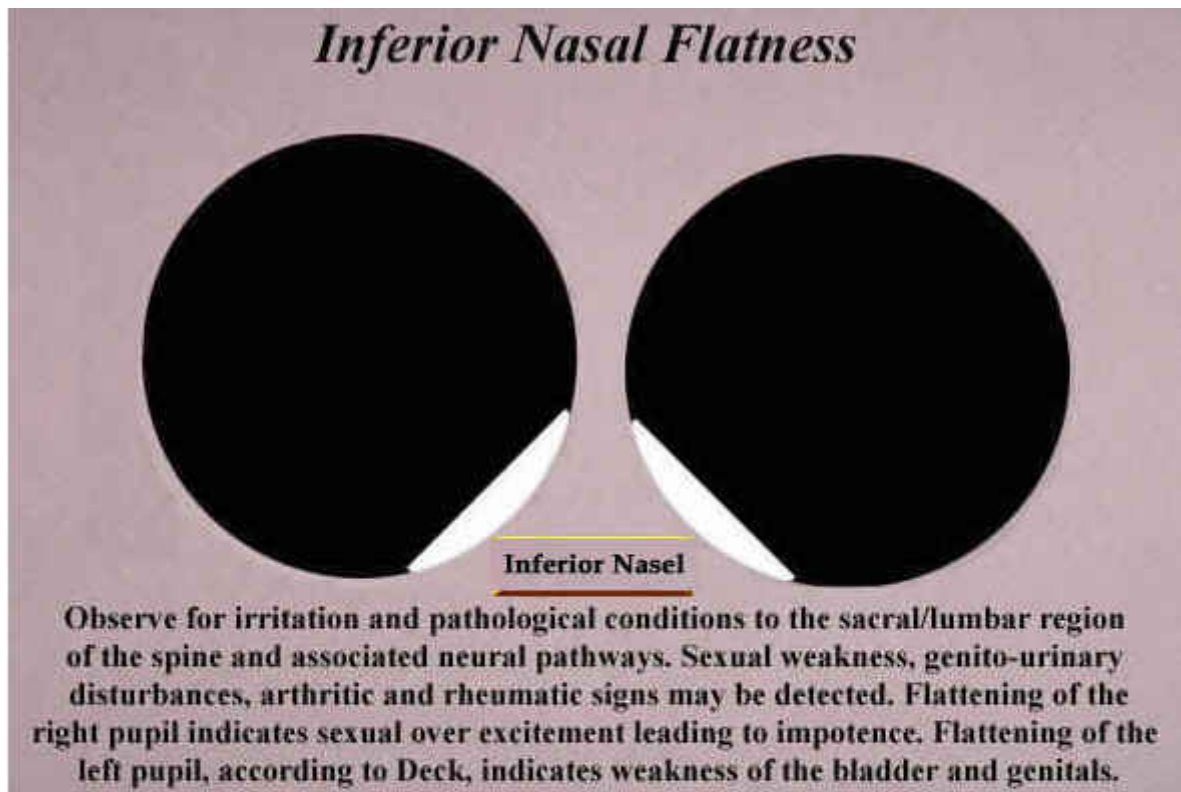
Potential history of diphtheria or meningitis, possible background of hereditary syphilitic damage.

Inferior Temporal flatness



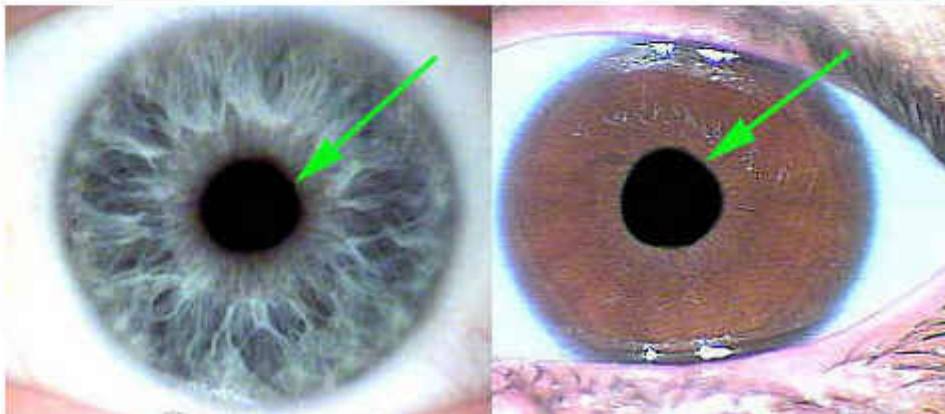
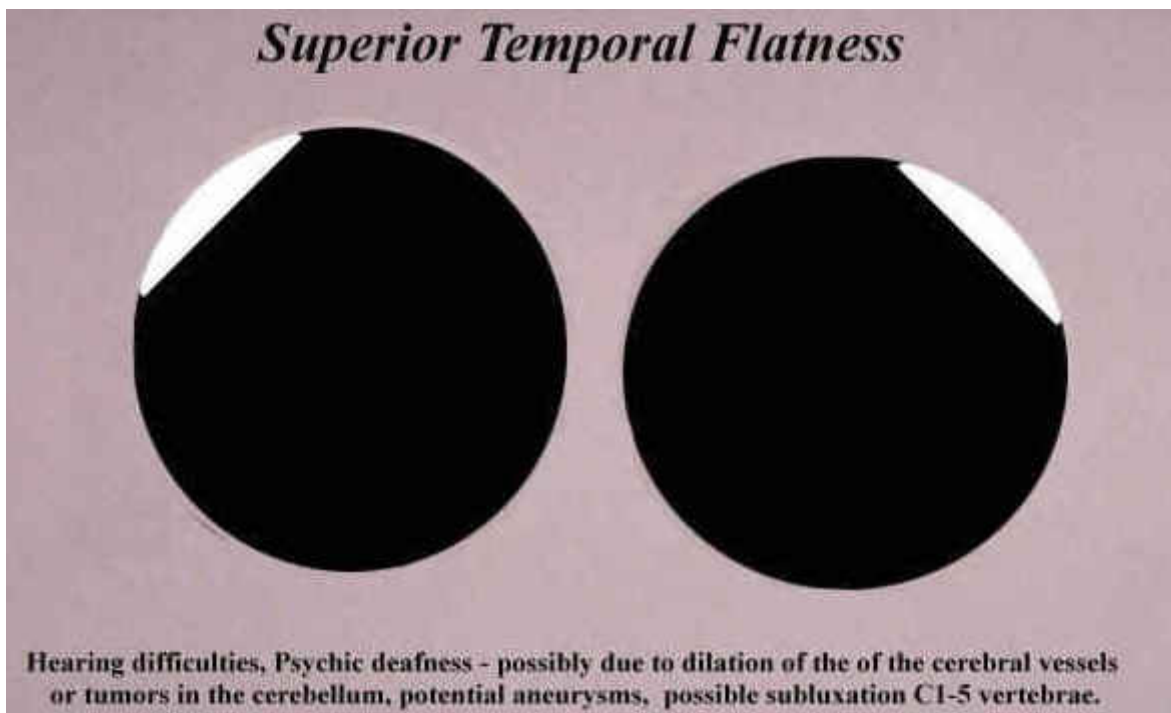
Observe for weakness in arm and shoulder movement, irritation and possible subluxation T1-4, T6 ??& 7 vertebrae, hepatic insufficiency. ? Problems with the movement of both arms and neuralgic pains may be indicated. The cause often stems from the cervical plexus. Muscle twitching along the spinal column can be seen showing nerve impulses being falsely directed. Flattening of the right pupil indicates liver and portal vein problems. Left pupil flattening indicates paralysis of the heart.

Inferior Nasal Flatness



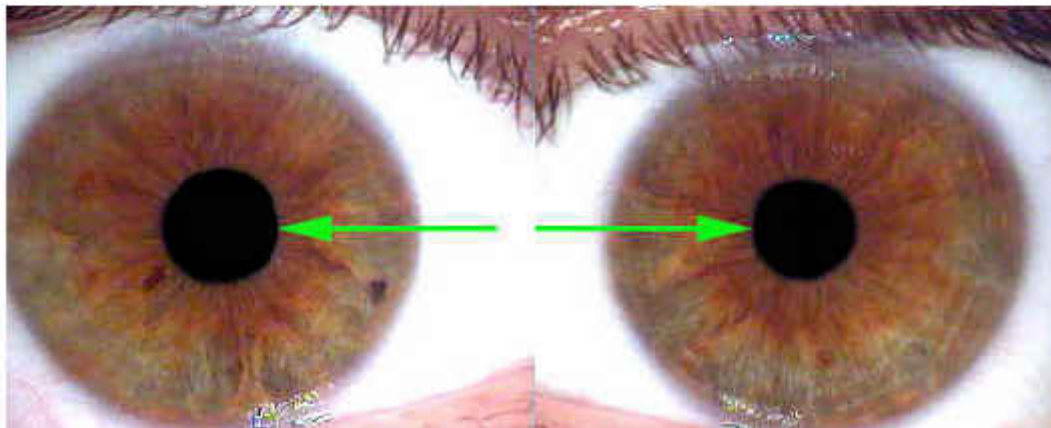
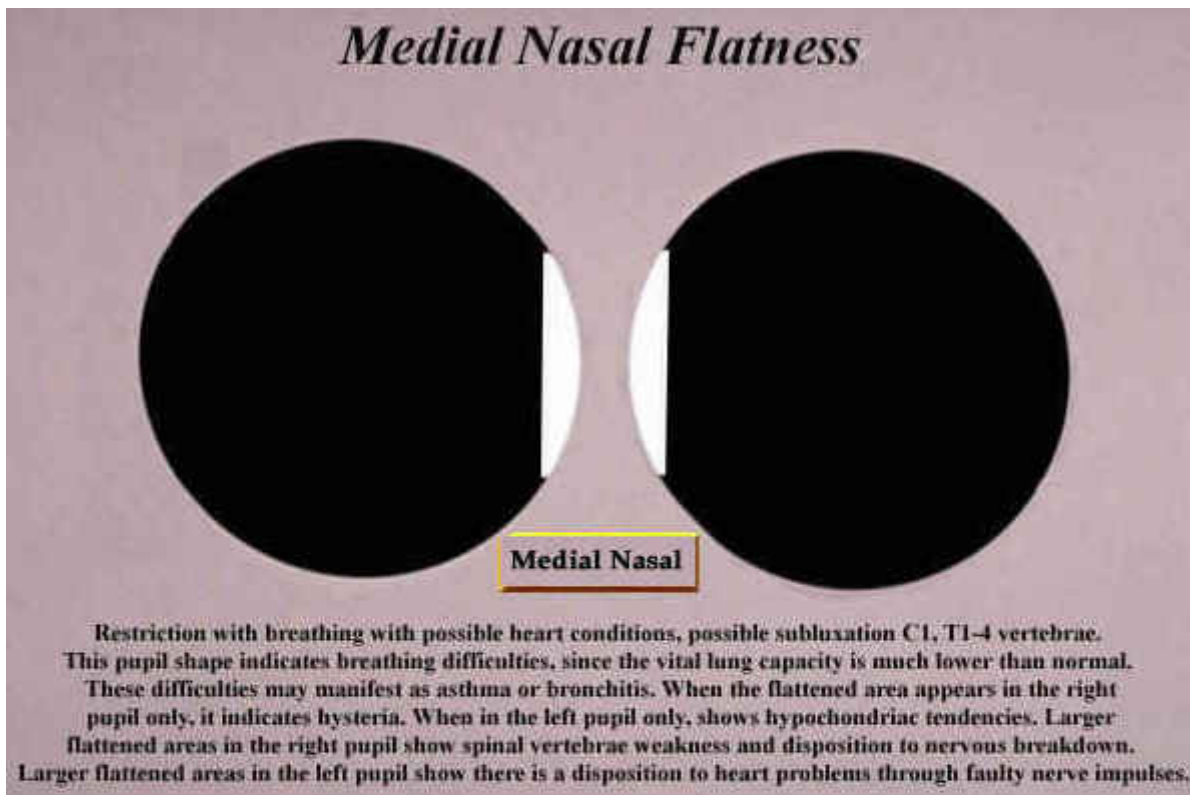
Observe for irritation to the sacral/lumbar region of the spine and associated neural pathways, genito-urinary disturbances, arthritic and rheumatic signs. Flattening of the right pupil indicates sexual over excitement leading to impotence. Flattening of the left pupil, according to Deck, indicates weakness of the bladder and genitals.

Superior Temporal Flatness



Hearing difficulties - possibly due to dilation of the of the cerebral vessels or tumors in the cerebellum, possible subluxation C1-5 vertebrae.

Medial Nasal Flatness



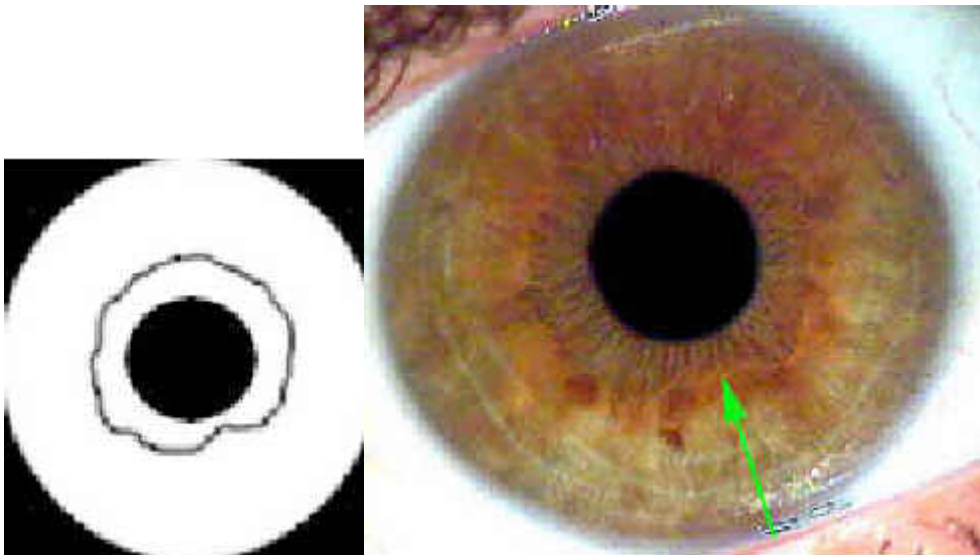
Restriction with breathing with possible heart conditions, possible subluxation C1, T1-4 vertebrae. This pupil shape indicates breathing difficulties, since the vital lung capacity is much lower than normal. These difficulties may manifest as asthma or bronchitis. When the flattened area appears in the right pupil only, it indicates hysteria. When in the left pupil only, shows hypochondriac tendencies. Larger flattened areas in the right pupil show spinal vertebrae weakness and disposition to nervous breakdown. Larger flattened areas in the left pupil show there is a disposition to heart problems through faulty nerve impulses.

The Autonomic Nerve Wreath

The collarette or “Autonomic Nerve Wreath” is one of the most important landmarks that an Iridologist will analyze. The collarette is exemplified as a vascular analog for the autonomic nervous system. This circular phenomena is described as a representative for the exchange of nutrients and toxic material between the intestinal tract and the humors of the body. This would also include the collarette serving as an index for the lining of the intestinal tract and autonomic nervous system.

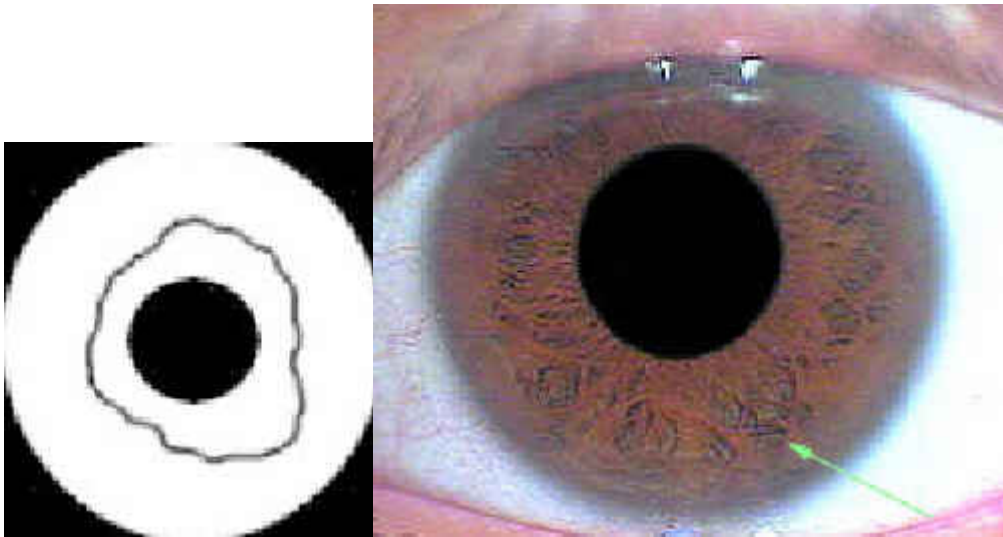
Just a few Autonomic Nerve Wreath Examples are listed below. More information about the Autonomic Nerve Wreath can be obtained from CNRI Educational Programs.

Indented Collarette



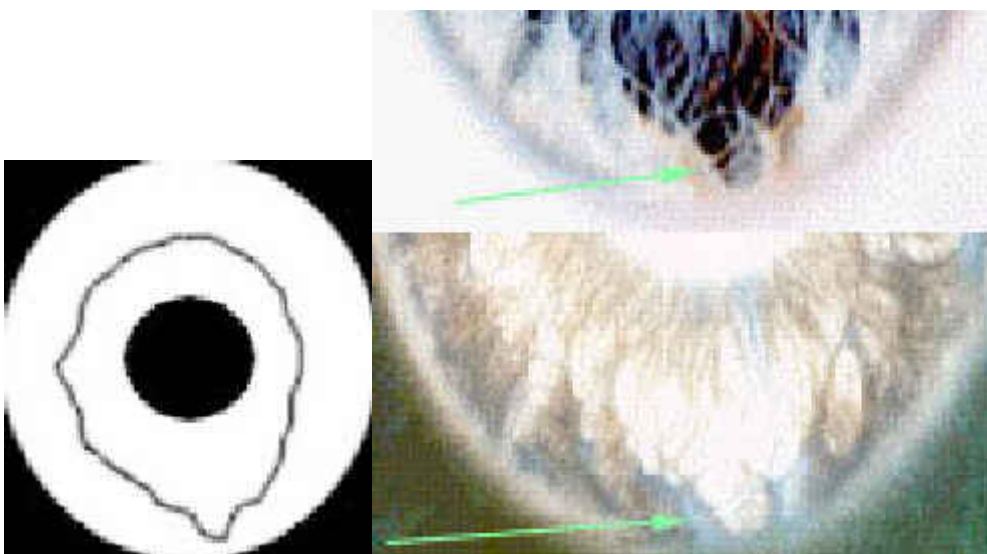
Represents a narrowing of the pupillary zone. Also known as the Centripetal type, a tendency towards hypertonicity (tenseness) of the gastrointestinal tract with a disposition to the spastic variety of constipation.?

Lateral Distention



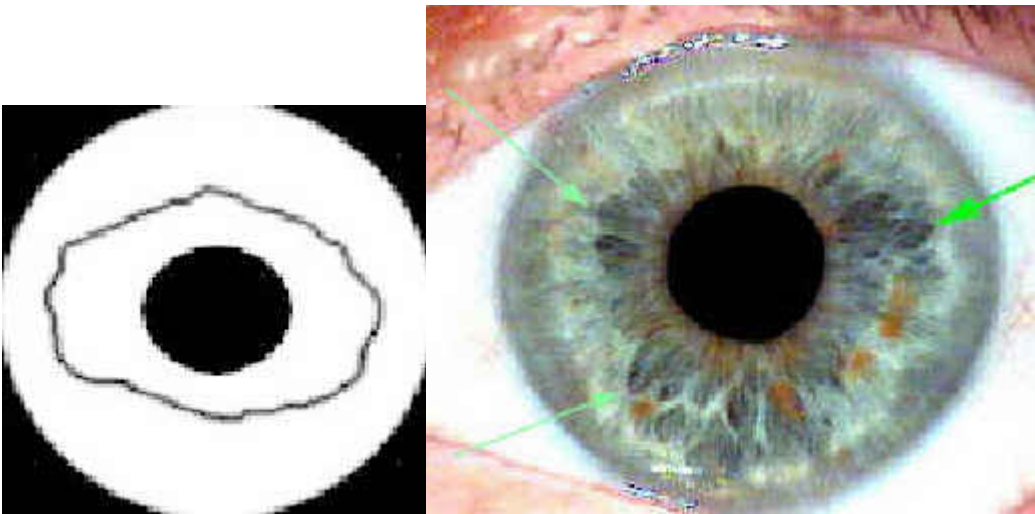
Tendency towards weak intestinal peristalsis with slow transit time. Potential colon prolapsus, ?cardio-abdominal symptoms, dysbacteria and dysfunction of the ANS fibers in the muscular coats of the intestine. If distention is seen in the left iris, disturbances of the spleen and /or pancreas tail may be found. Lower capacity to digest small amounts of food are indicated. When distention is found in the right iris, disturbances of liver metabolic functions may be detected. A tendency towards hemorrhoids may be indicated.

Ventral Distention



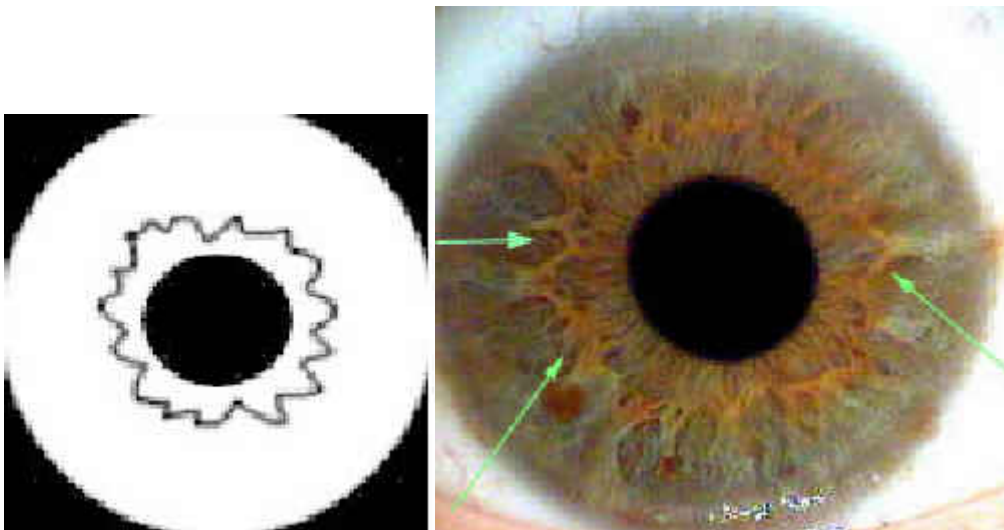
Indicates a slackening of the Tonus of the abdominal blood vessels. Tendency towards hemorrhoids, enteroptosis, prostate hypertrophy, low back pains, energetic weakness in lower extremities.

Bilateral Distention



?Indicates a slackening of the small and large intestines. Tendency towards chronic atonic constipation, dysbacteria and flatulence. ?

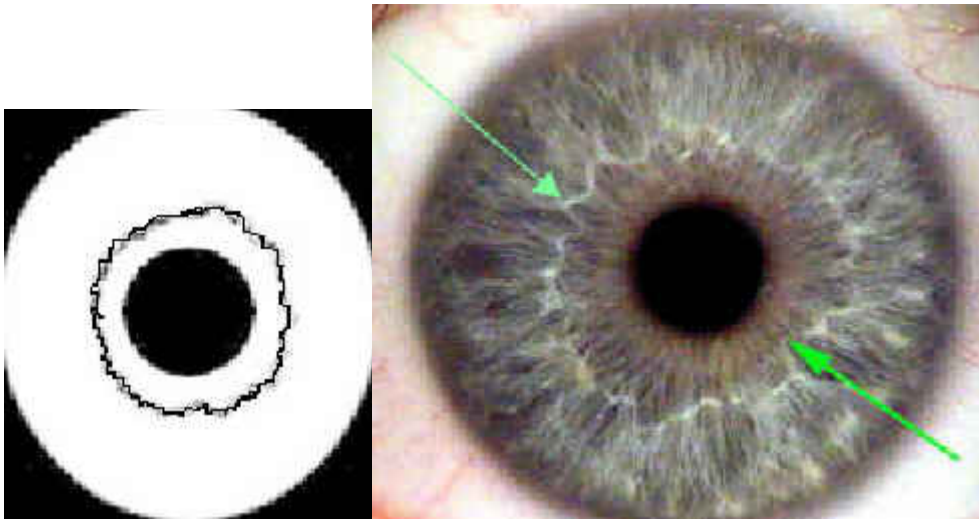
Zig-Zag Collarette



?Represents ?a hyperkinetic gastrointestinal tract that can include accelerated transit time, spastic constipation and colic. Psychological tendencies such as mood swings and anxiousness.

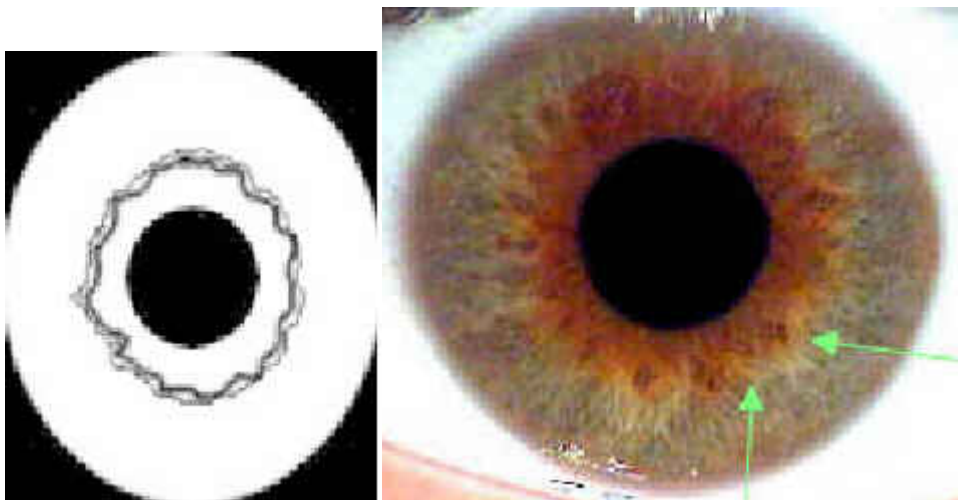
Collarette Structure

Hyperplastic



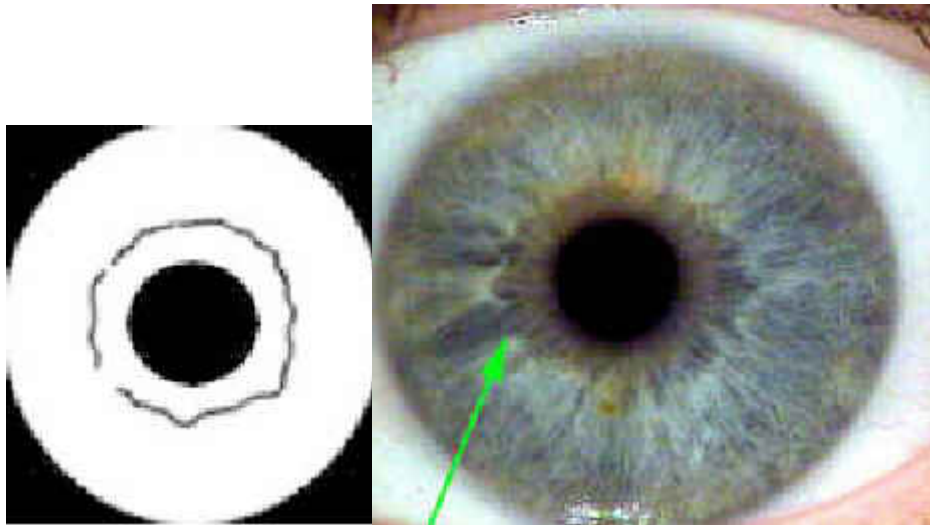
Denotes a lightened or thickened collarette representing an irritable autonomic nervous system. It is an indication of decompensation mechanisms in the GI tract, such as dysfermentia, flatulence, increased peristalsis and painful spasms. A very bright collaratte may be significant of over-acidity in the GI tract leading to allergic states, food intolerance's and a variety of "itis" type conditions.

Parallel Track



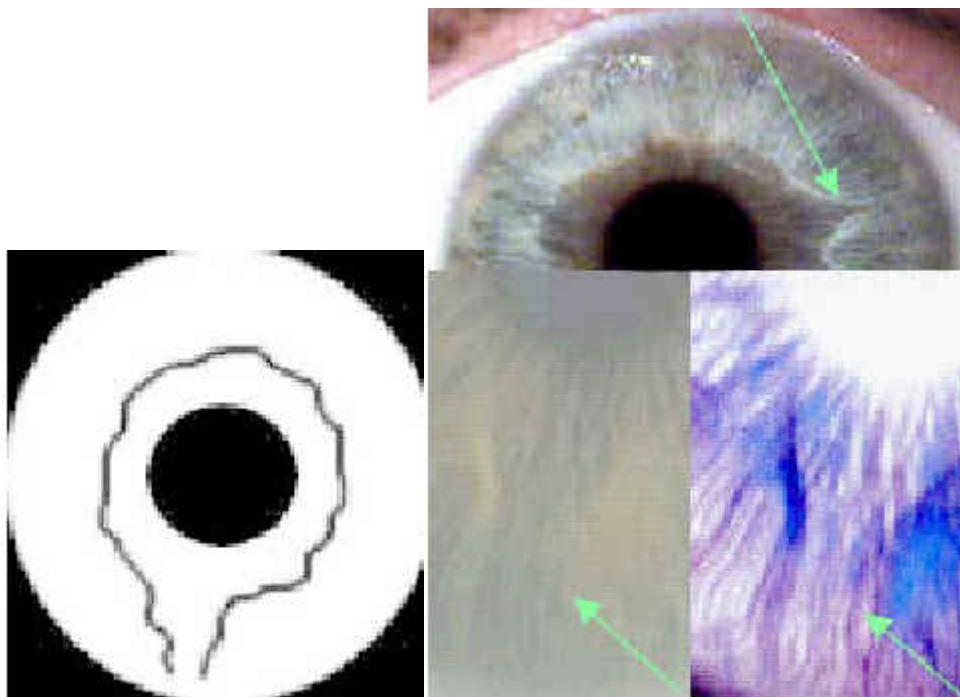
Also known as the double collarette, represents psychoneurotic and psychosomatic tendencies. This is inherited characteristic and there may be family history of apathy, depression and suicide. If this sign is found temporally or medially, possible nervous asthma, cardiac rhythmic disorders and cardiac neurosis may be indicated. ?

Sectoral Absence



A poorly defined or absent collarette indicates an insufficient autonomic nervous system with inhibited regulatory capacity. Reaction and resistance to negative influences is usually difficult. There is often association with psycho-emotional disturbances producing hopelessness and fatigue symptoms. If detected in children, possibilities of intestinal colic, low calcium absorption, bone development disturbances, stomach \ appetite weakness, food intolerance's, nausea, excess catarrh, may be indicated.??A sectoral absence may be interpreted as inhibition of enzyme synthesis in the digestive tract with poor vitamin absorption, especially vitamin A.||sectoral

Funnel



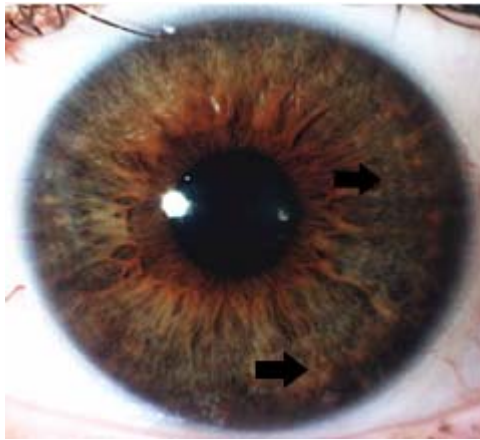
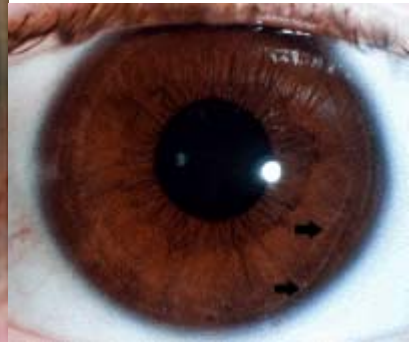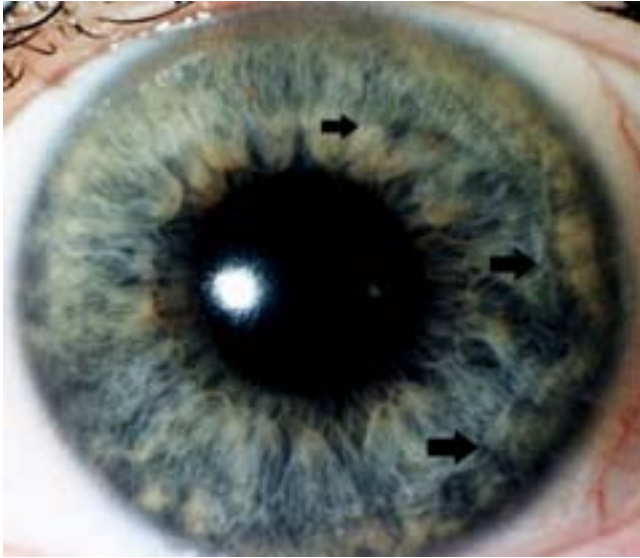The funnel type appearance is an indication of weak muscle and connective tissue. Possible hernias and other tissue

displacements may be considered.

Adaptive Rings and Arcs of the Iris

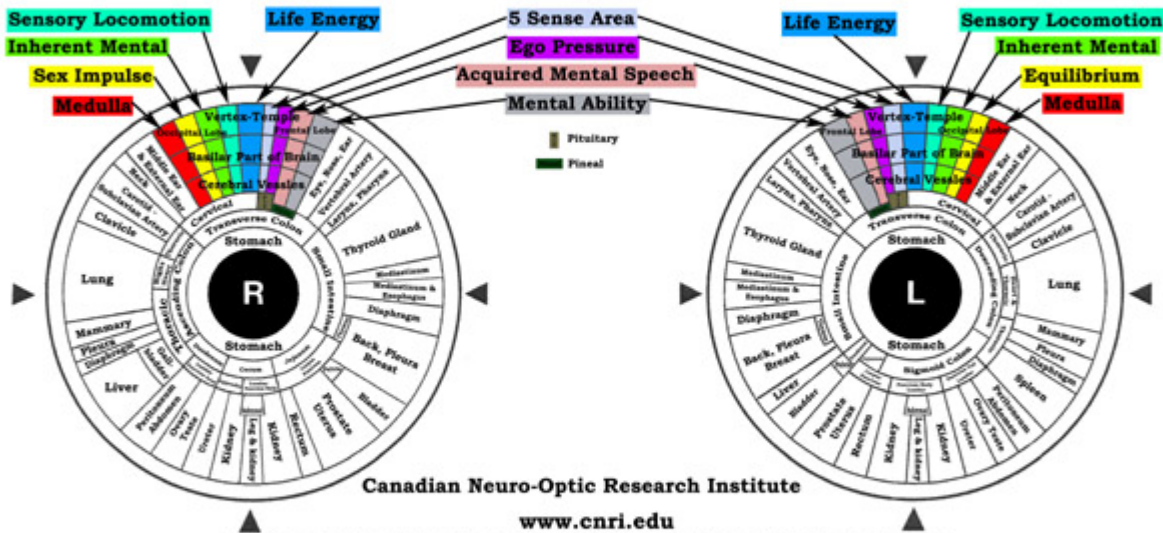
Ophthalmologists consider contraction rings to be the simple folds of the iris, and explain their origination by the work of neuro-motor apparatus of eye, contraction, and dilation of the superficial layers of iris. However, iridologists think that some other factors should be taken into consideration: histologically there is no anterior boundary layer at the level of the mentioned folds, they are present far from all people, while multiple dilation and contraction of the pupil occur in every iris; they usually don't have regular shape; and, above all, folds are not increased considerably in mydriasis and are decreased in miosis. There are some differences in opinion between several iridological schools regarding adaptive rings. Some iridologists consider adaptive rings to be the phenomenon, associated with the change of metabolic processes activity, which always leads to the reduction of the tissue elasticity and with age - to sclerotic changes in the organism. They think that such reasons as traumas, inflammations, overloads with medicines, meals with high calcium contents, are of prior importance for adaptive rings formation.

Other iridologists associate these iridological signs with the prolonged overload of the sympathetic nervous system, having an influence on the pupil dilator tonus. They assert that exact constriction of the dilator with the simultaneous relaxation of sphincter leads to the formation of the concentric folds and furrows, which are a non-specific reactive phenomenon. Thereby they consider the strong emotions, physical and psychical overloads, stress states, different pains and irritants to be the main reasons of adaptive ring formation. Most of these iridologists think that people with such signs are sensitive persons, trying not to reveal their emotions, but to hide them inside. The fact that in the most active period of life maximal adaptive rings are present on the iris and in the period of progressive aging - minimal amount, indicates that there is no direct connection between the diseases and adaptive rings, otherwise their maximum must be in the elderly age with multiple diseases and deviations from the normal state. Adaptive rings help to evaluate psycho-emotional tension of a person, which is necessary on psycho-neurological practice, especially in those cases where behind the external tranquillity and steadiness, a labile and hyper-sensitive person is hiding.



Integrative Iridology Chart

Bryan K. Marcia, Ph.D.



One of the most controversial questions in iridology is the vast amount (40 Plus) of Iridology projection charts. It has been distinguished that around 70% of iridology charts correspond with each other and around 25% of differences can be justified by the following important factors:

- 1: Limitations of possible shift of organs projections.
- 2: Differences in size, form and location of the organs can be the rationale of the corresponding individual features of topography.
- 3: Different variants of laterality (true and partial left-handers) cause the significant topographic confusions.
- 4: In the majority of charts the possibility of superposition of different organs projections, distortions, caused by the shifted projection of the neighboring organs, 'irido-aggressive zones' must be taken into consideration.
- 5: The pathological processes, changing the dimensions of various organs can lead to the pronounced shift of coordinates in the iris due to their dilation or reduction.

Iridology Clinical Studies and Supplemental Rebuttals

Many email inquiries looking for clinical studies accomplished in Iridology come to CNRI from students in several Colleges and Universities worldwide.

This page will assist them in their search for such studies and to encourage further discussion, research and development in Iridology.

In the past 10 years of lurking around health related UseNet Newsgroups, I occasionally see posts about two particular Medline abstracts debunking Iridology. To discard Iridology as a contributing science on the basis of only a few questionable clinical trials is ridiculous!

Why are these medline-JAMA clinical studies flawed? Mainly because they used incorrect methods of iris photography. They had only took General Photos of the eyes. The eyeball is round in shape just like the earth, not flat as some societies had thought some time ago.. If the eyeball was flat, perhaps their clinical studies could have been more successful?

Read on and decide for yourself...

Sector Photography Research by Joseph Deck

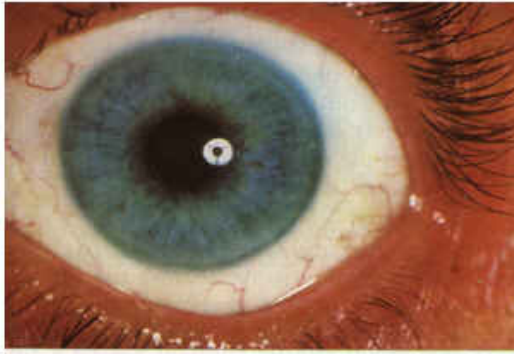


Photo 1: General photo of left iris

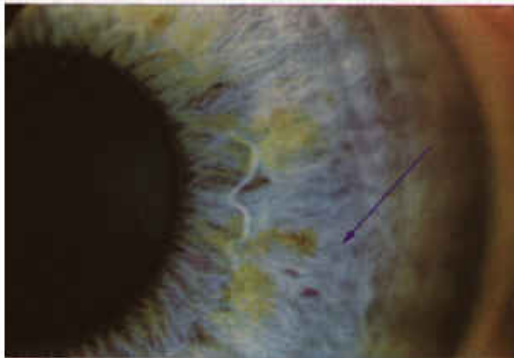

Photo 2: Sector photograph with depth of pupillary margin and iris collarette sharply focused (Zone 1)

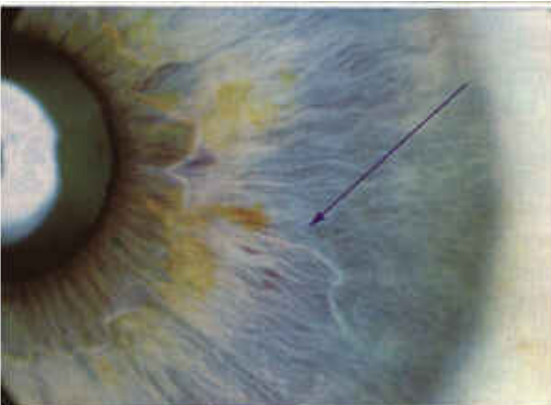


Photo 3: Zone II is sharply focused

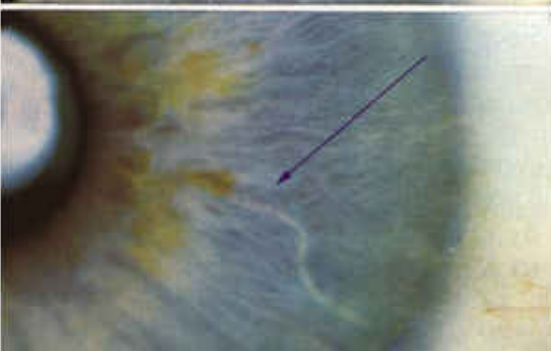


Photo 4: Zone III sharply focused

This is why sector photography must be used in clinical trials. By missing the transversal in photo 1 or 2 (Arrow pointing toward it) would result in error of any clinical study in Iridology not using sector photography AND via live microscope. This method was not used in the Iridology clinical abstracts found in Medline.

I have also listed rebuttals for two Medline abstracts in question. Read them and you decide.. I wish to thank both authors Harri Wolf, M.A. and Bill Caradonna R.Ph. for their kind permission to post these great rebuttals on the Internet!

*** Please note that many of these manuscripts have been translated from other languages and you may find some unusual grammar or pronunciation.**